

## SUBFOVEAL CHOROIDAL THICKNESS CHANGE FOLLOWING STRABISMUS SURGERY

ŞAŞILIK CERRAHİSİ SONRASI SUBFOVEAL KOROID KALINLIĞINDAKİ DEĞİŞİKLİKLER

Hatice Tuba ATALAY, Yavuz Kemal ARIBAŞ, Ahmet Yücel ÜÇGÜL, Mehmet Cüneyt ÖZMEN

Gazi Üniversitesi, Tıp Fakültesi Göz Hastalıkları Anabilim Dalı

### ÖZ

**AMAÇ:** Şaşılık cerrahisinin subfoveal koroid kalınlığı üzerine etkilerini araştırmak.

**GEREÇ VE YÖNTEM:** Şaşılık cerrahisi geçiren hastaların subfoveal koroid kalınlık (KK) ölçümleri optik koherens tomografi (EDI-OCT) ile elde edildi. Hastalar 1 rektus kas cerrahisi geçirenler (superior; inferior; medial ya da lateral; ve rezeksiyon veya geriletme) (Grup 1) ve inferior oblik kas cerrahisi geçirenler (miyektomi) (Grup 2) olarak sınıflandı. Hastaların preoperatif, postoperatif ilk gün ve postoperatif 1. hafta KK ölçümleri kaydedildi.

**BULGULAR:** Çalışmaya 41 hastanın 41 gözü dahil edildi. Grup 1'deki preoperatif, postoperatif birinci gün ve birinci hafta ortalama subfoveal KK'ların sırasıyla  $390.57 \pm 89.54 \mu\text{m}$ ,  $415.23 \pm 91.77 \mu\text{m}$  ve  $394.8 \pm 90.97 \mu\text{m}$  olduğu tespit edildi. Grup 1'de preoperatif ve postoperatif ilk gün karşılaştırıldığında KK'da bir artış olduğu izlendi ( $p = 0.002$ ). Ayrıca, grup 1'de postoperatif ilk gün ve 1.hafta karşılaştırıldığında, istatistiksel olarak anlamlı bir düşüş bulundu ( $p = 0.007$ ). Grup 2'de preoperatif, postoperatif ilk gün ve postoperatif 1. hafta ortalama subfoveal KK'ları sırasıyla  $347.75 \pm 83.58 \mu\text{m}$ ,  $332.75 \pm 84.95 \mu\text{m}$  ve  $332 \pm 79.15 \mu\text{m}$  idi. Preoperatif ve postoperatif ilk gün KK'ları karşılaştırıldığında istatistiksel olarak anlamlı olmayan bir düşüş gösterdi ( $p = 0.532$ ).

**SONUÇ:** Rektus kası cerrahisi subfoveal KK'da artışa neden olmaktadır, bunun cerrahi sırasındaki mekanik traksiyon, değişen koroid mikrosirkülasyon ve postoperatif inflamasyona bağlı olduğunu düşünmekteyiz. Grup 2'de benzer bir artış görmemizin nedeni; inferior oblik kasın maküler bölgedeki traksiyonunun gevşemesi ve nispeten düşük bir postoperatif inflamasyon nedeniyle olabilir.

**ANAHTAR KELİMELEER:** Koroid kalınlığı, Şaşılık Cerrahisi, Optik Koherens Tomografi

### ABSTRACT

**OBJECTIVE:** To investigate the effect of strabismus surgery on subfoveal choroidal thickness (CT).

**MATERIAL AND METHODS:** Measurements of subfoveal CT in patients who underwent strabismus surgery were obtained by enhanced depth imaging optic coherence tomography (EDI-OCT). Patients were grouped as those who had had one rectus muscle surgery (superior; inferior; medial or lateral; or resection or recession) (Group 1) and those who had had inferior oblique muscle surgery (myectomy) (Group 2). The CT in patients was measured preoperatively and at one day and one week postoperatively.

**RESULTS:** Included in the study were 41 eyes of 41 patients. It was found that the preoperative, first day postoperative, and first week postoperative mean subfoveal CTs in Group 1 were  $390.57 \pm 89.54 \mu\text{m}$ ,  $415.23 \pm 91.77 \mu\text{m}$ , and  $394.8 \pm 90.97 \mu\text{m}$ , respectively. The preoperative and first-day postoperative comparison revealed an increase in CT ( $p=0.002$ ). However, when the first day postoperative and first-week postoperative measurements were compared, a statistically significant decrease was found ( $p=0.007$ ). In Group 2, the preoperative, first day postoperative, and first week postoperative mean subfoveal CTs were  $347.75 \pm 83.58 \mu\text{m}$ ,  $332.75 \pm 84.95 \mu\text{m}$ , and  $332 \pm 79.15 \mu\text{m}$ , respectively. The preoperative and first-day postoperative comparison showed a decrease in CT that was not statistically significant ( $p=0.532$ ).

**CONCLUSIONS:** Rectus muscle surgery causes an increase in subfoveal CT, which is possibly caused by the altered choroidal microcirculation mechanical traction during surgery and by postoperative inflammation. We did not see a similar increase in Group 2; this may be due to the relaxation of the inferior oblique muscle's traction in the macular region and a relatively low level of postoperative inflammation.

**KEYWORDS:** Choroidal thickness, Strabismus Surgery, Optical Coherence Tomography

**Geliş Tarihi / Received:** 10.06.2019

**Kabul Tarihi / Accepted:** 03.07.2019

**Yazışma Adresi / Correspondence:** Dr.Öğr.Üyesi Hatice Tuba ATALAY

Gazi Üniversitesi Tıp Fakültesi Göz Hastalıkları Anabilim Dalı

htatalay@yahoo.com

## INTRODUCTION

The choroid is responsible for feeding the outer retinal segments, which are placed between the lamina fusca of the sclera and the retina pigment epithelium. Choroidal thickness (CT) differs according to age, sex, refractive status, and circadian rhythm (1,2). Choroidal changes are involved in the pathogenesis of many diseases, including choroidal neovascularization, central serous chorioretinopathy, and polypoidal choroidal vasculopathy (3,6). In order to understand the pathophysiology associated with CT, studies related to choroidal change are being conducted at an increasing rate.

Strabismus surgery is one of the most commonly performed ophthalmic surgeries and has a significant impact on patients' quality of life. Recently, subclinical foveal and perifoveal macular thickening following extraocular muscle surgery have been reported (7). Because the retina and choroid are adjacent anatomical structures, we may expect a similar relationship between strabismus surgery and CT. In this study, we used enhanced depth imaging optical coherence tomography (EDI-OCT) to investigate the change in subfoveal CT after rectus and inferior oblique muscle surgeries in patients with strabismus.

## MATERIALS AND METHODS

### Institutional review board approval

This retrospective study was conducted with the approval of the Institutional Review Board of the Gazi University School of Medicine and was performed in accordance with the ethical principles described in the Declaration of Helsinki. Informed consent was obtained from all the enrolled patients.

Patients with any known systemic diseases or severe ocular diseases including uveitis, glaucoma, and vascular or inflammatory retinal diseases were excluded from the study, as were patients who had undergone ocular surgery previously. In total, 41 eyes of 41 patients who had undergone uncomplicated rectus muscle or inferior oblique muscle surgeries for strabismus were entered into this study. Patients were grouped as those who had had one rectus muscle surgery (superior; inferi-

or; medial or lateral; or resection or recession) (Group 1) and those who had had inferior oblique muscle surgery (myectomy) (Group 2).

All surgeries were performed by the same surgeon (HTA). The rectus muscle surgeries were performed via limbal incision, while the inferior oblique myectomies were performed through fornix incision. A 6-0 Vicryl was used for the muscle suturing, and a 7-0 Vicryl was used for conjunctival closure. The patients were administered a combination of topical tobramycin and dexamethasone for one week after the surgery.

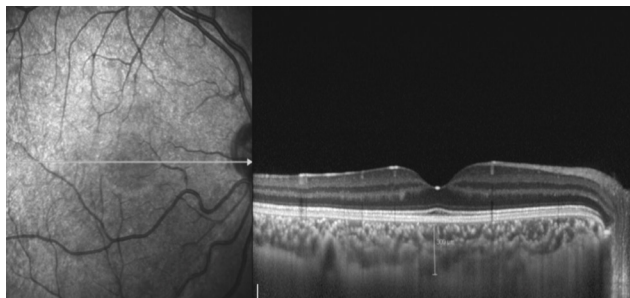
A detailed ophthalmologic examination was performed preoperatively. EDI-OCT measurements were obtained on the morning of the surgery (between 8 - 9 am) in order to refrain from diurnal fluctuations. Examinations and EDI-OCT measurements were performed before surgery (as a baseline) and were repeated at the first day and first week postoperatively.

### Image acquisition and processing

Choroidal imaging was performed using the enhanced depth imaging (EDI) mode of the Heidelberg spectral domain optical coherence tomography (SD-OCT) system. (Heidelberg Engineering, Heidelberg, Germany). After properly positioning the patient's head and chin, the patient was told to maintain fixation on the internal fixation light while a reverse image was obtained from the fundus, which was then automatically inverted in order to maintain the chorioretinal interface in zero delay. In a rectangular area of 5° x 30° including macula and optic nerve, 13 sections, and 768 A-scans, were taken. For the CT measurement, one section, passing through the fovea horizontally, was used. The distance between the outer margin of hyperreflective retinal pigment epithelium and the inner border of the sclera was measured for CT (**Figure 1**).

Only images with a minimum signal strength of 45 were taken. CT measurements were performed manually by two different physicians, who were blind to each other. The average of the two measurements was calculated. The difference between the measurements of the two physicians was within 10% of the average.

**Figure 1:** CT measurement, the choroidal margins were taken as the distance between the outer margin of hyperreflective retinal pigment epithelium and the internal side of the sclera.



## STATISTICAL ANALYSIS

All data were analyzed using SPSS software (Version 16.0, SPSS Inc., Chicago, IL, USA). Normality of the data was analyzed by Shapiro-Wilk test found to be non-normally distributed. Wilcoxon signed-rank test was used for the comparison between the preoperative and postoperative measurements. The Mann-Whitney U test was used for the comparison of age between groups. The Chi-square test was used for the comparison of gender between groups. Evaluations were made at a 95% confidence interval, and a p-value of <0.05 was considered statistically significant.

## RESULTS

A total of 41 eyes of 41 patients were included, with mean patient age of  $19.76 \pm 15.48$  years in Group 1 (13 men and 13 women) and  $16.25 \pm 10.91$  years in Group 2 (8 women and 7 men). There were no significant differences with regard to gender ( $p=0.643$ ) or age ( $p=0.660$ ) between the groups.

The preoperative, first day postoperative, and first week postoperative mean subfoveal CT measurements in Group 1 were  $390.57 \pm 89.54$   $\mu\text{m}$ ,  $415.23 \pm 91.77$   $\mu\text{m}$ , and  $394.8 \pm 90.97$   $\mu\text{m}$ , respectively.

The preoperative and first-day postoperative comparison revealed an increase in CT ( $p=0.002$ ). However, when the first day postoperative and first-week postoperative measurements were compared, a statistically significant decrease was found ( $p=0.007$ ).

The preoperative, first day postoperative, and first week postoperative mean subfoveal CTs in Group 2 were  $347.75 \pm 83.58$ ,  $332.75 \pm 84.95$ , and  $332 \pm 79.15$ , respectively. The preoperative and first-day postoperative comparison revealed a decrease that was not statistically significant ( $p=0.532$ ). No statistically significant difference was found between the preoperative and first week postoperative subfoveal CTs in either group ( $p=0.686$ ;  $p=0.780$ ) (**Table 1**).

**Table 1:** Average subfoveal CT measurements.

	Preop CT	Postop Day 1	Postop Week 1	P value <sup>a</sup>	P value <sup>b</sup>	P value <sup>c</sup>
Group 1	390.57±89.54	415.23±91.77	394.8±90.97	0.002	0.007	0.686
Group 2	347.75±83.58	332.75±84.95	332±79.15	0.532	0.649	0.780

a: For Wilcoxon test between preoperative and first day postoperative measurements

b: For Wilcoxon test between first day and first week postoperative measurements

c: For Wilcoxon test between preoperative and first week postoperative measurements

## DISCUSSION

The choroid is essential for the oxygenation of the outer retinal layers up to the inner nuclear layer and is particularly important for feeding the foveal avascular zone. Developments in OCT technology have allowed for a more detailed examination of the choroid (8).

In the present study, our aim was to evaluate the change in subfoveal CT after rectus and inferior oblique muscle surgeries in patients with strabismus. The subfoveal CT increased temporarily in Group 1, but there was not a significant change in that of Group 2.

The anterior ciliary arteries (ACA) run along with the rectus muscles and have been estimated to provide 70%–80% of the blood supply to the anterior segment (9). A study by Kimura et al. found a temporary increase in CT after scleral buckle surgery. They suggested that the increase in CT may be due to a reversible subclinical microcirculatory alteration of the choroid as a result of venous drainage obstruction (10). Based on the results of our study, it is possible that the disruption of ACAs and anterior ciliary circulation and venous drainage obstruction-induced by the recession/resection of a rectus muscle-led to hemostasis in choroidal circulation, resulting in subfoveal choroidal thickening in Group 1. The absence

of any intervention to disturb the hemostasis during inferior oblique myectomy may explain the absence of the increase in CT in Group 2. Another possible explanation for our findings is that the temporary increase in subfoveal CT may be related to periocular inflammation. It has been suggested that the increase in CT may be due to proinflammatory cytokines and prostaglandins, which are believed to be released after cataract surgery (11). These inflammatory mediators go through the vitreous to the retina and impair inner and outer blood-retinal barrier (12). The inflammation, which develops following rectus muscle surgery, might cause inflammatory cascades in the posterior segment. The difference in CT changes between Group 1 and Group 2 may be due to the difference in the degree of inflammation between the two groups. The use of different surgical techniques -limbal incision rather than fornix incision and applying more mechanical traction to rectus muscles during recession/ resection and re-suturing in Group 1 may have further increased the amount of inflammation (12). Shorter duration of surgery might have caused less inflammation in the inferior oblique group (Group 2).

We believe that, in group 2, the relaxation of the inferior oblique muscle's traction at the insertion site to the macular region is one of the reasons that subfoveal CT remained stable.

In a study by Ercan et al., the severity of the inferior oblique overaction was shown to have no effect on subfoveal CT (13). Contrary to our study, a study by Inan et al. found a decrease in subfoveal CT after both rectus muscle surgeries and inferior oblique recession (14). In their study, the reason for the decrease in CT after inferior oblique recession may be due to the better preservation of the vascular structure in that region compared to that which occurs in myectomy. Unlike Inan et al., we found an increase in the subfoveal CT at the rectus muscle group instead of a decrease. This difference might be due to the use of limbal incision instead of a fornix incision in our study, as greater inflammation occurs following a limbal incision (12,14). This study is limited by its relatively small sample size and that it does not include all possible combinations of muscle surgery. Another limitation is that the study evaluated only

the early effects of surgery on subfoveal CT. In conclusion, our study emphasizes the possibility of a temporary change in subfoveal CT after rectus muscle surgery. Reversible subclinical microcirculatory dysfunction of the choroid, postoperative inflammation, or mechanical traction during surgery may be the triggers for choroidal alterations. Further studies are necessary to clarify the relationship between circulatory alteration, periocular inflammation, mechanical factors, and changes in subfoveal CT.

### Declaration of Interest

The authors report no financial or business conflicts of interest to declare.

### REFERENCES

1. Wei WB, Xu L, Jonas JB, et al. Subfoveal choroidal thickness: The Beijing Eye Study. *Ophthalmology*. 2013;120(1):175-180.
2. Tan CS, Ouyang Y, Ruiz H, et al. Diurnal variation of choroidal thickness in normal, healthy subjects measured by spectral domain optical coherence tomography. *Investig Ophthalmol Vis Sci*. 2012;53(1):261-266.
3. Grossniklaus HE, Green WR. Choroidal neovascularization. *Am J Ophthalmol*. 2004;137(3):496-503.
4. Gomi F, Tano Y. Polypoidal choroidal vasculopathy and treatments. *Curr Opin Ophthalmol*. 2008;19(3):208-212.
5. Iida T, Kishi S, Hagimura N, et al. Persistent and bilateral choroidal vascular abnormalities in central serous chorioretinopathy. *Retina*. 1999;19(6):508-512.
6. Gupta P, Cheung CY, Saw SM, et al. Peripapillary choroidal thickness in young Asians with high myopia. *Investig Ophthalmol Vis Sci*. 2015;56(3):1475-1481.
7. Mintz HR, Waisbourd M, Kessner R, et al. Macular thickness following strabismus surgery as determined by optical coherence tomography. *J Pediatr Ophthalmol Strabismus*. 2016(Jan.-Feb.);53(1):11-15.
8. Lavers H, Zambarakji H. Enhanced depth imaging-OCT of the choroid: a review of the current literature. *Graefes Arch Clin Exp Ophthalmol*. 2014;52(12):1871-1883.
9. Wilcox LM, Keough EM, Connally RJ, et al. The contribution of blood flow by the anterior ciliary arteries to the anterior segment in the primate eye. *Exp Eye Res*. 1980;30:167-74.
10. Kimura M, Nishimura A, Yokogawa H, et al. Subfoveal choroidal thickness change following segmental scleral buckling for rhegmatogenous retinal detachment. *Am J Ophthalmol*. 2012;154(5):893-900.

- 11.** Xu H, Chen M, Forrester JV, et al. Cataract surgery induces retinal pro-inflammatory gene expression and protein secretion. *Investig Ophthalmol Vis Sci.* 2011;52(1):249-255.
- 12.** Tso MO, Shih CY. Experimental macular edema after lens extraction. *Investig Ophthalmol Vis Sci.* 1977;16(5):381-392.
- 13.** Mikhail M, Verran R, Farrokhyar F, et al. Choice of conjunctival incisions for horizontal rectus muscle surgery--a survey of American Association for Pediatric Ophthalmology and Strabismus members. *J AAPOS.* 2013;17(2):184-187.
- 14.** Ersan I, Oltulu R, Altunkaya O, et al. Relationship of inferior oblique overaction to macular and subfoveal choroidal thickness. *J AAPOS.* 2015;19(1):21-23.
- 15.** Inan K, Niyaz L. The effect of strabismus surgery on choroidal thickness. *Eur J Ophthalmol.* 2018;28(3):268-271.