

Received: 2019.12.04  
Accepted: 2020.04.28  
Available online: 2020.05.18  
Published: 2020.06.17

## Cholecysto-Hydatid Cyst Fistula: A Rare Cause of Cholangitis

Authors' Contribution:  
Study Design A  
Data Collection B  
Statistical Analysis C  
Data Interpretation D  
Manuscript Preparation E  
Literature Search F  
Funds Collection G

ABEF 1 **Mehlika Bilgi Kırmacı**  
ABEG 2 **Tamer Akay**  
BCD 3 **Esra Özgül**  
ABCDEF 1 **Sezgin Yılmaz**

1 Department of General Surgery, Faculty of Medicine, Afyonkarahisar Health Sciences University, Afyonkarahisar, Turkey  
2 General Surgery Clinic, Bandırma State Hospital, Balıkesir, Turkey  
3 Department of Radiology, Faculty of Medicine, Afyonkarahisar Health Sciences University, Afyonkarahisar, Turkey

**Corresponding Author:** Mehlika Bilgi Kırmacı, e-mail: mehlikabilgi@hotmail.com  
**Conflict of interest:** None declared

**Patient:** Female, 76-year-old  
**Final Diagnosis:** Left hepatic cyst hidatic fistula to gall bladder  
**Symptoms:** Biliary colic • icterus • Sepsis  
**Medication:** —  
**Clinical Procedure:** Multidiscipliner treatment  
**Specialty:** Surgery

**Objective:** Rare disease





**Background:** Cholecysto-hydatid fistula is a rare complication of liver echinococcosis; suppurative cholangitis due to cholecysto-hydatid fistula is even rarer. A multidisciplinary approach is required by radiology and surgery departments during the preoperative diagnosis and treatment processes of these cases. In this paper, a patient treated with suppurative cholangitis due to cholecysto-hydatid fistula is presented.

**Case Report:** A 76-year-old female patient was admitted to emergency services due to cholangitis. Abdominal computerized tomography (CT) examination revealed that the common bile duct was dilated through the right liver in a wide and torsional pattern; the gallbladder cleaved into hepatic flexura and its wall became irregular. There was a cystic appearance 10×13×12 cm in size on the lateral segment of the left liver lobe. Endoscopic retrograde cholangiopancreatography (ERCP) was performed, and it showed the communication between the hydatid cyst pouch and the bile duct. The patient was taken to open surgery, which confirmed the imaging findings. The gallbladder and the adjacent cyst were excised, and a T-tube was placed in the choledochus. Postoperative recovery was uneventful.

**Conclusions:** We suggest that cholecysto-hydatid fistula is a severe problem that requires close workup with both the radiology and surgery departments. Preoperative ERCP is beneficial for the visualization of the fistulization between gallbladder and hydatid cyst and for the treatment of suppurative cholangitis.

**MeSH Keywords:** Biliary Fistula • Cholangiopancreatography, Endoscopic Retrograde • Cholangitis • Echinococcosis, Hepatic • Gallbladder Diseases

**Full-text PDF:** <https://www.amjcaserep.com/abstract/index/idArt/921914>

 1449   4  15



## Background

The liver is the most frequently affected organ in echinococcosis [1]. A common and severe complication in hepatic hydatid cyst disease is the communication between the cyst and the biliary tree [2]. However, fistulization between gallbladder and hydatid cyst is rare. The number of cases in the literature is below 10.

Although its etiopathogenesis is not known, there are several theories about the relationship between acute cholecystitis and cyst hydatid fistulae: either an inflammation caused by acute cholecystitis, or inflammation of the gallbladder by a hydatid cyst, leading the cyst to open to the gallbladder.

In addition, cyst hydatid-gallbladder fistulae may sometimes rupture and cause the cyst content to spread to the peritoneal cavity, which results in peritonitis or intra-abdominal abscess [1]. The diagnosis is difficult, and a collaboration between radiology and surgery departments is indispensable. Ultrasonography (USG) and computed tomography (CT) can show the communication, but endoscopic retrograde cholangiopancreatography (ERCP) can detect the fistulization in detail. However, in occasional cases, the diagnosis can only be made by laparotomy [3]. Although the communication of a hepatic hydatid cyst with the gallbladder is a severe problem, cholangitis rarely occurs as the fistula between gallbladder and cyst hydatid needs to be large enough to pass the cyst material into the gallbladder. Besides, the cystic duct needs to be wide and short enough to pass these materials to the bile duct lumen. Finally, obstructive jaundice occurs if the hydatid materials (hydatid sand, daughter cysts, membrane particles) freely empties into the choledochus. We have previously reported that ERCP could be used successfully to remove parasites from the biliary tree in cases with cholangitis [4]. Thus, ERCP could be considered as the initial treatment method for cysto-hydatid fistula to treat cholangitis in addition to the diagnosis. The detection of the endoscopic method used (endoscopic sphincterotomy, nasobiliary drainage or biliary stent placement) depends on both the clinical condition of the patient and the cholangiographic view [5,6]. Hence, we believe that combined endoscopic-surgical approach is useful for treating cholecysto-hydatid fistula.

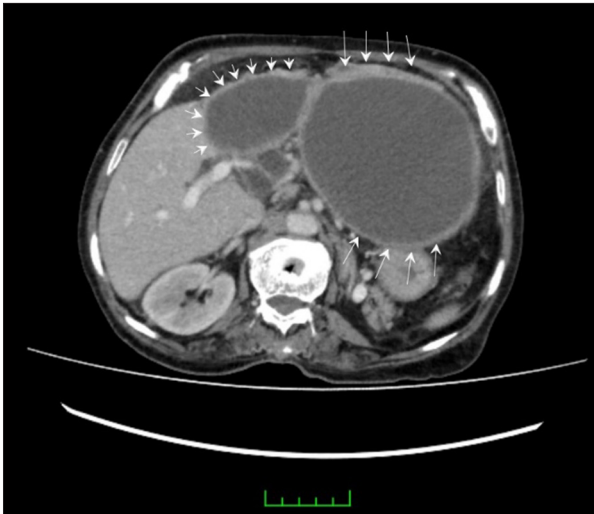
## Case Report

A 76-year-old female patient was referred to emergency services with the complaint of acute abdominal pain in the right hypochondrium, fever, and jaundice. She had a history of pain in the right hypochondrium and epigastrium for the last 2 weeks.

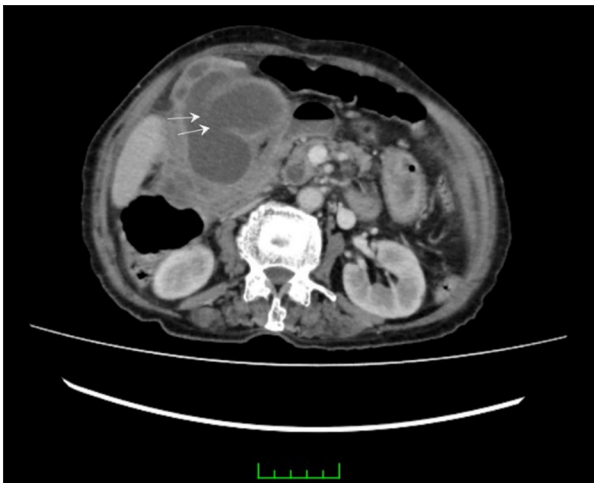
Laboratory findings were as follows: direct bilirubin 2.2 mg/dL, amylase 304 U/L, alkaline phosphatase 829 U/L, gamma glutamyl transferase 575 U/L, white blood cell  $20.14 \times 10^3$  U/L. The laboratory examinations of the patient were compatible with obstructive jaundice. The patient was diagnosed with cholangitis due to the presence of pain, fever (39°C), and jaundice. Imaging methods were applied to identify the etiology. CT imaging revealed that the diameter of the common bile duct was increased, measured at 14 mm at the distal part. Bilobar intra-hepatic biliary tracts were also apparent. The gallbladder was hydropic and adherent to the hepatic flexura, and its wall was irregular (possible gallbladder perforation). Minimal pericholecystic fluid collection was observed. Common bile duct was narrowed at the lower end (possible stone or tumor). There was a cystic appearance  $10 \times 13 \times 12$  cm in size on the medial-lateral segment of the left lobe of the liver, which pushed the pancreas and stomach to the left side. There was a slight connection between the gallbladder and hydatid cyst. Contamination was observed on the head and neck of the pancreas (Figures 1, 2).

ERCP was planned following CT evaluation. When endoscopic sphincterotomy was performed during the ERCP procedure, suppurative exudative fluid and membranous structures were extracted from the bile duct (possible hydatid cyst). Contrast materials flowing from the gallbladder to the hydatid cyst were observed, and a cholecysto-hydatid fistula was suspected (Figure 3).

After the ERCP procedure, the symptoms of the patient improved significantly. Hydatid cyst antibody test was performed by the enzyme-linked immunosorbent assay (ELISA) method. During treatment, 250 mg (2×1) albendazole was initiated for hydatid cyst treatment, and 1 g (2×1) ceftriaxone and 500 mg (3×1) metronidazole were initiated for cholangitis treatment. The patient was taken to operation 3 days after ERCP. Open surgery was performed, and cholecystectomy fistulization was detected between the gallbladder and hydatid cyst. Pericystectomy was performed along with cholecystectomy following sterilization maneuvers for cyst hydatids. The postoperative period was uneventful. The patient was discharged on the eighth day after the operation. Histopathologic report verified the hydatid cyst fistula to the gallbladder as we suspected, and no stone was found (Figure 4). After 1 month from surgery, neither peritonitis nor intra-abdominal abscess occurred at the follow-up abdominal CT. The patient received followed up by the Infectious Diseases Department of our university at 3-week intervals, and the treatment was to be reorganized according to hydatid antibody level after 6 months.



**Figure 1.** Computed tomography images show that there were 2 thick-walled cysts compatible with hydatid cyst (short and long arrows).

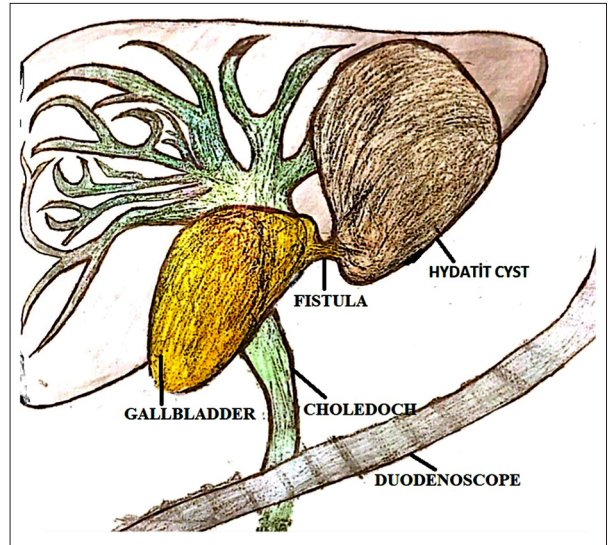


**Figure 2.** Computed tomography images of the wide and short fistula neck between the gallbladder and the hydatid cyst.

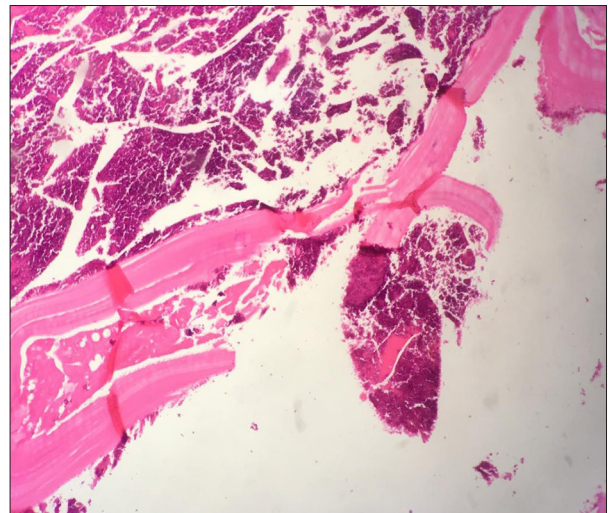
## Discussion

Cyst hydatid is a zoonosis arising from the larval stage of the *Echinococcus* species. Clinical characteristics of cyst hydatid disease depend on the area, size, and developmental stage of the cyst, whether the cyst is dead or alive, and complications. Infection and continuous extension of the cyst can cause compression, erosion, and adhesion to adjacent structures. In time, the cyst ruptures from the increasing intracystic compression. Inflammation leads to necrosis and causes fistulization [7].

Intrahepatic complications of the hydatid cyst include cyst rupture and infection. Rupture to the biliary tree is the most common complication, seen in 5% to 15% of cases. It is seen



**Figure 3.** Endoscopic retrograde cholangiopancreatography illustration of gallbladder fistulation of hydatid cyst in the left lobe of the liver. The cyst was enlarged in nearly all of the left lobe.



**Figure 4.** Histopathology image of the hydatid cyst wall consisting of an avascular, eosinophilic chitinous laminated membrane (hematoxylin and eosin stain 100×).

in the right duct in 55% to 60% of cases and in the left duct in 25% to 30%, and rarely in the junction point or gallbladder. The cause for this seems to be the inclusion of biliary radicals into the pericyst during growth [8]. In our present case, it was seen that the hydatid cyst extended to the gallbladder and made a connection between them.

It has been reported that biliary obstruction occurs in 5% to 17% of cases after the hepatic hydatid cyst is ruptured [9]. Jaundice, fever, and chills are the most frequently seen symptoms related

with biliary obstruction and cholangitis [10]. Obstructive jaundice occurs in 57% to 100% of cases following intrabiliary rupture, particularly when the rupture occurs in the large biliary duct. Thus, the contents are discharged into the biliary ducts. The transmission of cystic content into the biliary duct occurs in 65% of cases where the cystobiliary gap is larger than 5 mm [11]. In the present case, cyst contents passed to the gallbladder at first. Then, they dropped to the choledochus and produced the symptoms related with cholangitis since the cystic duct was wide enough. It seems that the membranes stayed within the choledochus and obstructed the bile duct lumen further, causing obstructive jaundice. The management of cysto-hydatid fistula requires a multi-disciplinary approach of radiology and surgery departments for early diagnosis and requires a combined endoscopic-surgical approach afterwards. The reported success rate of preoperative endoscopic interventions including endoscopic sphincterotomy, extraction of biliary contents, nasobiliary drainage and/or stent placement is over 80% [12]. In the treatment of our patient, performing ERCP in the first stage not only enabled us to make the diagnosis more accurately but also provided a more minimally invasive surgical treatment. ERCP may cause contrast cholecystitis (30%), an infection of cyst cavitation, pancreatitis, bleeding, infection, or perforation. In addition, patients are exposed to anesthesia twice [13]. In the series reported by Rodriguez et al., patients undergoing preoperative ERCP developed uncontrollable fistulae [14]. Patients should be observed for these risks.

Additional advantages of endoscopic treatment for hepatic cyst hydatid patients are that it allows for elective surgery and significantly decreases the morbidity and mortality associated with the procedure. In the present case, since the thickness of cyst was strong enough to prevent spillage of cyst material according to CT image, we did not think that ERCP increased the risk of capsular outflow.

## References:

1. Sabat SB, Barhate KP, Deshmukh MP: Cholecysto-hydatid cyst fistula. *J Ultrasound Med*, 2008; 27: 299–301
2. Sharma BC, Reddy RS, Garg V: Endoscopic management of hepatic hydatid cyst with biliary communication. *Dig Endosc*, 2012; 24: 267–70
3. Luks B, Dworzyńska A, Dobrogowski M: Cholecysto-hydatid cyst fistula complicated by cholecystitis and acute rupture hydatid cyst into peritoneal cavity – A case report. *J Liver Clin Res*, 2017; 4(1): 1029
4. Yılmaz S, Akıcı M, Şimşek M et al: Endoscopic retrograde cholangiopancreatography for biliary system parasites. *Turk J Surg*, 2018; 34(4): 306–10
5. Foutch GP, Harlan JR, Hoefler M: Endoscopic therapy for patients with a postoperative biliary leak. *Gastrointest Endosc*, 1993; 39: 416–21
6. Davids PHP, Rauws EA, Tytgat GNJ, Huibregste K: Postoperative bile leakage: Endoscopic management. *Gut*, 1992; 33: 1118–22
7. Kismet K, Ozcan AH, Sabuncuoglu MZ et al: A rare case: Spontaneous cutaneous fistula of infected splenic hydatid cyst. *World J Gastroenterol*, 2006; 12: 2633–35
8. Pedrosa I, Saiz A, Arrazola J et al: Hydatid disease: Radiologic and pathologic features and complications. *Radiographics*, 2000; 20: 795–817
9. Akkiz H, Akinoglu A, Colakoglu S et al: Endoscopic management of biliary hydatid disease. *Can J Surg*, 1996; 39: 287–92
10. Ulualp KM, Aydemir I, Senturk H: Management of intrabiliary rupture of hydatid cyst of the liver. *World J Surg*, 1995; 19: 720–24
11. Zauouche A, Haouet K, Jouini M et al: Management of liver hydatid cysts with a large bilio-cystic fistula: Multicenter retrospective study. *Tunisian Surgical Association World J Surg*, 2001; 25: 28–39
12. Şimşek H, Özaskan E, Sayek İ et al: Diagnostic and therapeutic ERCP in hepatic hydatid disease. *Gastrointest Endosc*, 2003; 58(3): 384–89
13. Rodriguez AN, Sánchez del Río AL, Alguacil LV et al: Effectiveness of endoscopic sphincterotomy in complicated hepatic hydatid disease. *Gastrointest Endosc*, 1998; 48: 593–97
14. Dolay K, Akbulut S: Role of endoscopic retrograde cholangiopancreatography in the management of hepatic hydatid disease. *World J Gastroenterol*, 2014; 20(41): 15253–61
15. Kumar A, Upadhyaya DN, Singh S et al: Cholecysto-hydatid cyst fistula. *Indian J Gastroenterol*, 2004; 23: 76–77

Treatment options include the sterilization and drainage of hydatid cyst followed by radical (total cysto-pericystectomy) or conservative (partial pericystectomy) excision along with cholecystectomy. Following common biliary duct investigation and biliary lavage, T-tube drainage or transduodenal sphincteroplasty may be carried out, particularly in fistulae larger than 5 mm, if preoperative ERCP was not performed [15]. Preoperative ERCP obviates the necessity of choledochotomy and T-tube drainage by performing sphincterotomy or stent placement. In our case, pericystectomy and cholecystectomy were performed to the patient, and the postoperative course was uneventful.

## Conclusions

The management of patients with cholecysto-hydatid fistulae requires close cooperation between radiology and surgery departments. Preoperative ERCP provides precise diagnosis and treatment of cholangitis. It also allows stent placement, which obviates choledochotomy and T-tube drainage during laparotomy. In conclusion, combined endoscopic-surgical approach provides valuable information for patients with cholecysto-hydatid fistulae.

## Ethics approval

This study was conducted in compliance with the Institutional Review Board (IRB) regulations (approval ID: 354-19) and the Declaration of Helsinki.

## Conflict of interest

None.