



Ganglioneuroblastoma: A Rare Tumor in Parapharyngeal Space

Şahin Ulu¹ , Abdullah Kınar² , Abdulkadir Bucak¹

ABSTRACT

Background: Ganglioneuroblastoma is a malignant tumor, usually found in the adrenal glands, retroperitoneal ganglions or posterior mediastinum. In the head and neck region, Ganglioneuroblastoma is presented as a sub-type of neuroblastoma that originated from the sympathetic chain. It is often found in the retropharyngeal area, and if it involves the neck region, it is often found in the carotid space posterior to vascular sheath.

Case Report: A 5-year-old girl was admitted to the pediatrics clinic with the complaint of a mass on the right side of her neck for about six months. Ultrasonography was carried out as an initial diagnostic tool, and it revealed a solid homogeneous mass. As a second-line diagnostic imaging method, Magnetic Resonance Imaging (MRI) was performed. The T2 weighted MRI sections showed a hyperintense mass was observed with an axial diameter of 37×40 mm and a craniocaudal diameter of 6 cm in the right parapharyngeal and prevertebral space. Although fine-needle aspiration biopsy (FNAB) was the first preferred biopsy method for neck masses, the FNAB report was inadequate. An incisional biopsy was carried out, and the pathology report described the tumor as ganglioneuroma. There were no immature/neuroblastic components in the serial sections. The patient was operated on transcervically. In the final pathology report, the tumor was described as ganglioneuroblastoma, intermixed type. After multidisciplinary consultations, the patient is still being followed with no further additional chemotherapy or radiotherapy.

Conclusion: Ganglioneuroblastoma is a rare tumor in the parapharyngeal region. A multidisciplinary approach is especially important in such kind of rare tumors.

Keywords: Pediatric otolaryngology, ganglioneuroblastoma, cervical ganglioneuroblastoma, parapharyngeal, parapharyngeal ganglioneuroblastoma

Cite this article as:
Ulu Ş, Kınar A, Bucak A.
Ganglioneuroblastoma:
A Rare Tumor in
Parapharyngeal Space.
Erciyas Med J 2020;
42(3): 339-42.

¹Department of Ear Nose and Throat Head and Neck Diseases, Afyonkarahisar Health Sciences University Faculty of Medicine, Afyonkarahisar, Turkey
²Department of Ear Nose and Throat Head and Neck Diseases, Afyonkarahisar State Hospital, Afyonkarahisar, Turkey

Submitted
20.09.2019

Accepted
09.04.2020

Available Online Date
16.06.2020

Correspondence
Abdullah Kınar,
Afyonkarahisar State Hospital,
Department of Ear Nose
and Throat Head and Neck
Diseases, Afyonkarahisar,
Turkey
Phone: +90 552 405 73 04
e-mail:
abdullahkinar@gmail.com

©Copyright 2020 by Erciyas
University Faculty of Medicine -
Available online at
www.erciyesmedj.com

INTRODUCTION

Parapharyngeal space ganglioneuromas or ganglioneuroblastomas in the pediatric population are very rare. The incidence of neuroblastic tumors in the whole body is 7.6 per 1 million in the United States. Head and neck tumors account for approximately 5% of all these tumors; therefore, ganglioneuroblastomas originating in the head and neck region are very rare (1, 2).

Primary neuroblastic tumors originate from neural crest cells and have three histological types as follows: neuroblastomas, ganglioneuroblastomas and ganglioneuromas. These are different developmental stages of the same disease. Neuroblastoma is the least differentiated form and has a high metastasis rate, ganglioneuroblastoma is an intermediate form and has metastatic potential, whereas ganglioneuroma is the matured form and has no metastatic potential (3).

In adults, parapharyngeal space tumors account for approximately 0.5% of all head and neck neoplasms. Tumors of this region are mainly salivary gland tumors, neurogenic tumors, and paragangliomas. In the pediatric population, parapharyngeal tumors are very rare and inflammation and related lymphadenopathy are commonly seen in the parapharyngeal space. In the pediatric population, salivary gland tumors are rarely seen in the parapharyngeal space. Benign parapharyngeal pediatric tumors are mostly neurogenic tumors like neurofibroma, neuroma, or ganglioneuroma. Other non-malignant tumors, such as lipoma, cystic hygroma, and branchial cysts, can also be observed in the parapharyngeal space. Malignant tumors of the pediatric head and neck neoplasms are mostly sarcomas, especially rhabdomyosarcoma neurogenic neoplasms (neuroblastoma, ganglioneuroblastoma), lymphomas, thyroid cancer, retinoblastomas and other rare diseases (3).

In this case report, we aim to present a rare tumor in a pediatric patient with ganglioneuroblastoma, its characteristic properties and surgical approach in the head and neck region and we reviewed the current literature about this subject.

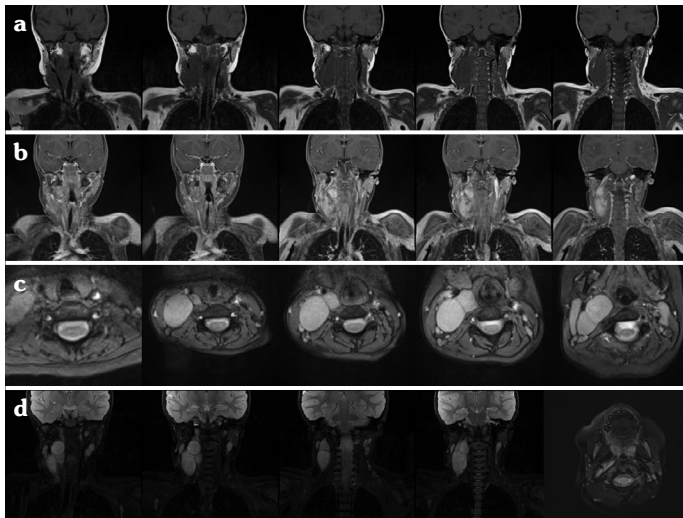


Figure 1. In the right parapharyngeal and prevertebral space, a mass is observed with an axial diameter of 37×40 mm and a craniocaudal diameter of 6 cm. In the A line, the tumor is observed hypointense in T1 weighted coronal sections, In the B line, the tumor is observed in fat suppression T1 weighted coronal sections. In the C line, the axial view of the tumor is observed. The tumor is located posterior to vascular structures and hyperintense in T2 weighted MRI sections. In the D line, the tumor is observed hyperintense in T2 weighted coronal sections and the last axial T2 weighted section, the tumor is extending through to the skull base is observed

CASE REPORT

A 5-year-old girl was admitted to the pediatrics clinic with the complaint of a mass on the right side of her neck for about six months. First, USG imaging was performed, which revealed a solid homogeneous and non-vascular mass. After that, an MRI was carried out. The MRI report described a mass with an axial diameter of 37×40 mm and a craniocaudal diameter of 6 cm observed in the right parapharyngeal and prevertebral space.

In Figure 1, preoperative MRI images of the tumor are presented.

Although fine-needle aspiration biopsy (FNAB) was the first preferred biopsy method for neck masses, the FNAB report was inadequate. Pediatric surgeons performed an incisional biopsy, and the pathology report described the tumor as ganglioneuroma. There were no immature/neuroblastic components in the serial sections. The patient was consulted from the pediatric surgery clinic to the ENT clinic (ear, nose, throat and head and neck diseases).

The patient was operated on transcervically. Intraoperatively, after a transcervical incision and working in the subplatysmal plane, anterior jugular vein ligated. The mass was respectful to the sternocleidomastoid muscle (SCM) and the mass separated from the muscle. Posterior belly of digastric muscle found and retracted. 11. CN, 12. CN, internal and external carotid artery, internal jugular vein protected while dissection. The tumor was deep to the vascular structures and the internal jugular vein was rudimentary. The internal jugular vein was separated from the carotid artery and vagus nerve. Sharp lancet dissection was done while separating

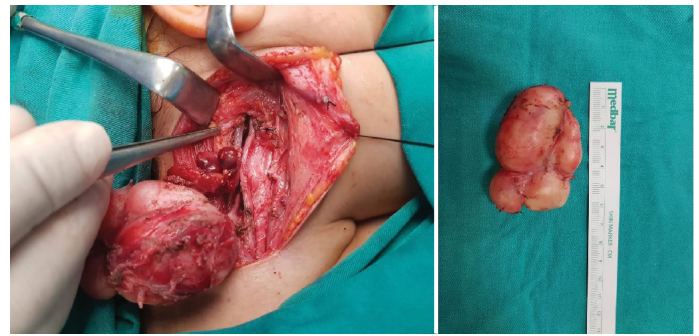


Figure 2. Intraoperative and excised view of the tumor. Note the carotid bifurcation, narrowed internal jugular vein, and parapharyngeal region. The tumor was excised carefully with magnifying loupe glasses. Sharp lancet dissection was done while separating the vagus nerve

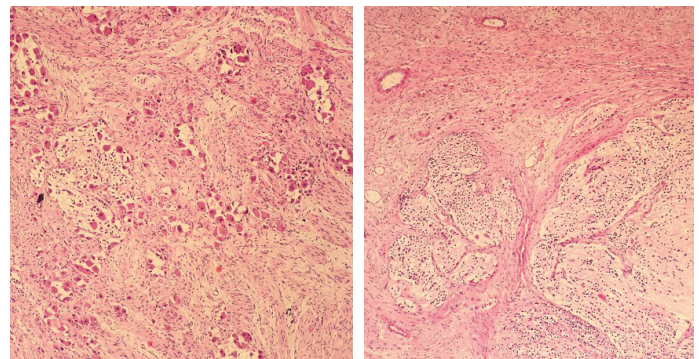


Figure 3. Microscopic view of the pathological specimen. Mostly spindle-like cells and in between the groups of hyperchromatic ganglion cells and immature neuroblastoma cells (H&E, ×200)

the tumor from the vagus nerve. The tumor was followed up and resected from the base of the skull to the entire neck. The tumor excised carefully with magnifying loupe glasses. The tumor was resected from the parapharyngeal space. The operation was concluded without any complications.

An intraoperative view of the tumor and a picture of the excised tumor are provided in Figure 2.

In the final pathology report, the tumor was concluded to be ganglioneuroblastoma, intermixed type.

A microscopic view of the tumor is provided in Figure 3.

Written consent was taken from the patient's parents for this case report.

DISCUSSION

Ganglioneuroblastoma is a malignant tumor, often found in the adrenal glands, retroperitoneal ganglions, or posterior mediastinum. In the head and neck region, Ganglioneuroblastoma presents as a sub-type of neuroblastoma from the sympathetic chain. It is often found in the carotid space posterior to the vascular sheath displacing the carotid and internal jugular vein anteriorly. It is well circumscribed and often extends the full length of the neck. On CT, the tumors frequently demonstrate calcification. On MRI,

the mass reveals a high-intensity signal on T1 Weighted and T2 Weighted sequences concerning muscle and enhancement. The location and the elongated “cigar” configuration of the mass in the patient’s age group is suggestive of a ganglionic tumor. Our patient’s tumor was consistent with this information. It was well-circumscribed and extended the full length of the neck and it was displacing the carotid and internal jugular vein (3).

Occasionally, ipsilateral ptosis and anisocoria (Horner syndrome) or heterochromia iridis may be a manifesting sign. The Horner syndrome is secondary to cervical sympathetic chain involvement, whereas the heterochromia reflects anomalous neural crest cell derivation. Dyspnea and feeding difficulties may occur due to direct tracheal or esophageal compression or may reflect the involvement of cranial nerve IX, X, XI, or XII. There were no symptoms in our patient.

A special diagnostic feature of neuroblastoma is the finding of elevated catecholamine levels in 70%–90% of patients; the substance usually measured is vanillylmandelic acid, and the most accurate determination requires a 24-hour urine collection. High catecholamine levels have been correlated with immature histology, large primary tumors, and advanced disease; elevated lactic dehydrogenase (LDH) levels are an additional unfavorable laboratory finding.

A patient with a functioning tumor may experience sweating, flushing, hypertension, diarrhea, and renal acidosis.

The examination of biopsy specimens by molecular genetic techniques, including proto-oncogene *N-myc* amplification, DNA ploidy, deletion of chromosome 1p, and expression of the *TRK* gene, appears to have prognostic significance, allowing stratification of patients into low-, intermediate-, or high-risk groups (3).

Our patient was five years old, and this case was generally consistent with the information provided.

Ganglioneuroblastoma treatment options are surgery, chemotherapy, or radiotherapy. Decisions about treatment modality should be based on the stage of the tumor, the age of the patient, and the biological prognostic factors. Surgical excision is the primary treatment method and postoperative morbidity should be minimal. The main aim of surgery is the complete removal of the tumor without damaging any important anatomical structures. Risk assessment should be performed before surgery.

Various surgical techniques have been described for parapharyngeal tumor surgery. The choice of approach is determined by the tumor size, location, vascularity, and histology. At the same time, a large intraoperative field of view should be provided for a safe surgical excision with clear margins and functional and cosmetic results (1).

A transcervical approach (with or without mandibulotomy), transoral approach, transcervical-transparotid approach, transparotid approach, transcervical-transmandibular approach, infratemporal fossa approach, or combined approaches can be used in the surgical intervention (1).

External approaches provide good access to parapharyngeal tumors, but there is a risk of cranial nerve deficit. These approaches are not safe in the case of tumors with a prominent vertical extension or radiological invasion into the cranial foramen (4). The tran-

soral approach is a direct approach to the tumor from the oropharynx, but this approach was found because of complications like as postoperative bleeding, fistulas, and nerve paralysis. The combined transoral-transcervical approach is also unsafe. Compared to the transcervical approach, the tumor could be residual, and the risk of neurovascular damage is higher than in the transcervical approach. Transoral robotic surgery for parapharyngeal benign tumors has shown good results (5, 6). However, very few centers around the world perform this technique.

In the transcervical approach, an incision is made at the hyoid level. Following the mobilization of the submandibular gland, the parapharyngeal space is reached. In this approach, with large vessels and nerves of the neck seen in the field of view, dissection may be difficult, especially at the base of the skull (4–7). Cranial nerve paralysis may occur. Particularly after the resectioning of neuroma or paraganglioma tumors of this region, the paresis of these cranial nerves has a poor prognosis (8). In our case, no cranial nerve paresis was observed after the ganglioneuroblastoma was excised.

Although the transcervical-transmandibular approach has disadvantages, such as transient tracheotomy, the requirement for mandibulotomy, and significant scarring, it provides a wide field of view both in the cervical region and at the base of the skull. Therefore, this method may be preferred for the removal of tumors at the base of the skull and large tumors. In the transparotid approach, following the completion of superficial parotidectomy, the facial nerve is released, and deep-lobe parotidectomy is done. The part of the tumor extending into the parapharyngeal region is then excised. Parotidectomy is a method that may be preferred in the surgical excision of deep-lobe tumors extending into the parapharyngeal region, also called “dumbbell tumors.” In such attempts, facial paralysis or paresis due to manipulation of the facial nerves can be expected. Tracheotomy was not required for our patient. Facial nerve risks, as in the transparotid approach, were not a problem in our surgical site.

During the dissection of the cranial nerves, the operation was continued with magnifying loupe glasses and it was completed without any complications. We completely removed our patient’s tumor by cervical approach. Thus, we did not experience any cosmetic or functional negative consequences. We furthermore did not encounter any cranial nerve paralysis. The patient did not develop any postoperative complications.

Lu et al. (7) suggested radiotherapy or chemotherapy if the tumor cannot be completely removed or is in a metastatic stage. In our case, chemotherapy and radiotherapy were not recommended due to the young age of the patient and the absence of metastasis. The tumor was excised completely, and adjuvant treatment was not administered.

The prognosis of ganglioneuroblastoma is associated with the age of the patient and the stage of the disease. Prognosis is good before six months of age; because they can regress completely or mature into ganglioneuromas. Disease recurrence usually occurs in the first two years, while 1% of the tumors metastasize to the liver, bone, brain, skin, or bone marrow with the lymphatic or hematogenous spread. Therefore, patients should be followed every three months in the first two years and every six months

thereafter. It should be noted that high levels of catecholamines may also be associated with recurrence (8).

Bolzacchi et al. (9) stated that blood and urinary catecholamine levels should be monitored, and imaging should be repeated at each follow-up visit. Also, bone scintigraphy is recommended every six months with I-metaiodobenzylguanidine (I-MIBG). In our case, the prognosis was good due to complete tumor excision. There is no recurrence or metastasis at three years after surgery. However, the patient is still being followed.

CONCLUSION

Ganglioneuroblastoma is a rare tumor in the parapharyngeal region. A multidisciplinary approach is especially important in such kind of rare tumors. The most suitable surgical technique should be selected for parapharyngeal region tumors because of their very critical anatomical location. In addition to the preservation of vascular and neural structures around the tumor during surgery, post-operative functional and cosmetic results are significant.

Informed Consent: Written consent was taken from the patient's parents for this case report.

Peer-review: Externally peer-reviewed.

Author Contributions: Concept – AK; Design – AK; Supervision – ŞU, AB; Materials – AK; Data Collection and/or Processing – AK; Analysis and/or Interpretation – AK; Literature Search – AK; Writing – AK; Critical Reviews – ŞU, AB.

Conflict of Interest: The authors have no conflict of interest to declare.

Financial Disclosure: The authors declared that this study has received no financial support.

REFERENCES

1. Kuet ML, Kasbekar AV, Masterson L, Jani P. Management of tumors arising from the parapharyngeal space: A systematic review of 1,293 cases reported over 25 years. *Laryngoscope* 2015; 125(6): 1372–81.
2. Manjaly JG, Alexander VR, Pepper CM, Ifeacho SN, Hewitt RJ, Hartley BE. Primary cervical ganglioneuroblastoma. *Int J Pediatr Otorhinolaryngol* 2015; 79(7): 1007–12. [\[CrossRef\]](#)
3. Bluestone CD, Simons JP, Healy GB. Bluestone and Stool's pediatric otolaryngology. 5th edition. USA: People's Medical Publishing House; 2014.p.1711–823.
4. Basaran B, Polat B, Unsaler S, Uluhan M, Aslan I, Hafiz G. Parapharyngeal space tumours: the efficiency of a transcervical approach without mandibulotomy through review of 44 cases. *Acta Otorhinolaryngol Ital* 2014; 34(5): 310–6.
5. Ansarin M, Tagliabue M, Chu F, Zorzi S, Proh M, Preda L. Transoral robotic surgery in
6. Lee HS, Kim J, Lee HJ, Koh YW, Choi EC. Transoral robotic surgery for neurogenic tumors of the prestyloid parapharyngeal space. *Auris Nasus Larynx* 2012; 39(4): 434–7. [\[CrossRef\]](#)
7. Lu D, Liu J, Chen Y, Chen F, Yang H. Primary cervical ganglioneuroblastoma: A case report. *Medicine (Baltimore)* 2018; 97(12): e0090.
8. Gauchan E, Sharma P, Ghartimagar D, Ghosh A. Ganglioneuroblastoma in a newborn with multiple metastases: a case report. *J Med Case Rep* 2017; 11(1): 239. [\[CrossRef\]](#)
9. Bolzacchini E, Martinelli B, Pinotti G. Adult onset of ganglioneuroblastoma of the adrenal gland: case report and review of the literature. *Surg Case Rep* 2015; 1: 79. [\[CrossRef\]](#)