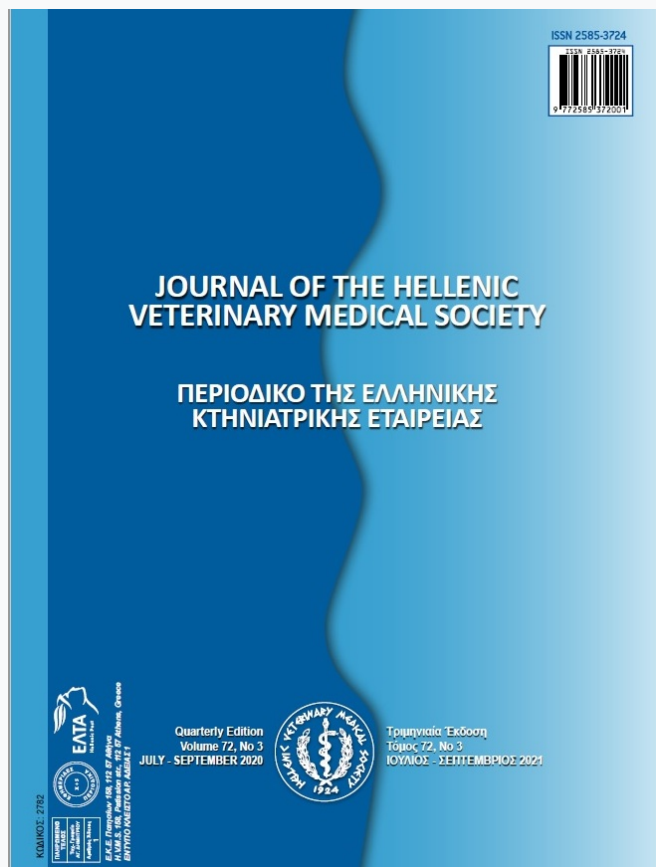

## Journal of the Hellenic Veterinary Medical Society

Vol 72, No 3 (2021)



### The antioxidant effect of *Michauxia campanuloides* on rat ovaries

S KURT, RH KOCA, MM HÜRKUL, U SEKER, A KÖROĞLU

doi: [10.12681/jhvms.28510](https://doi.org/10.12681/jhvms.28510)

#### To cite this article:

KURT, S., KOCA, R., HÜRKUL, M., SEKER, U., & KÖROĞLU, A. (2021). The antioxidant effect of *Michauxia campanuloides* on rat ovaries. *Journal of the Hellenic Veterinary Medical Society*, 72(3), 3163–3170. <https://doi.org/10.12681/jhvms.28510>

## The antioxidant effect of *Michauxia campanuloides* on rat ovaries

S. Kurt<sup>1\*</sup>, R. H. Koca<sup>2</sup>, M. M. Hürkul<sup>3</sup>, U. Seker<sup>4</sup>, A. Köroğlu<sup>3,5</sup>

<sup>1</sup>Dicle University, Faculty of Veterinary Medicine, Department of Obstetrics and Gynecology, Diyarbakir, Turkey

<sup>2</sup>Bingöl University, Faculty of Veterinary Medicine, Department of Reproduction and Artificial Insemination, Bingöl, Turkey

<sup>3</sup>Ankara University, Faculty of Pharmacy, Department of Pharmaceutical Botany, Ankara, Turkey

<sup>4</sup>Dicle University, Faculty of Medicine, Department of Histology and Embryology, Diyarbakir, Turkey

<sup>5</sup>Afyonkarahisar Health Sciences University, Faculty of Pharmacy, Afyonkarahisar, Turkey

**ABSTRACT:** This study investigated how *Michauxia campanuloides* affects the Proliferating Cell Nuclear Antigen (PCNA) expression in granulosa cells, the ovarian histomorphology and serum total antioxidant capacity (TAC) in rats. Rats were divided into control (C), treatment 1 (T 1) and treatment 2 (T 2) groups. The rats in the T 1 and T 2 groups received aqueous extract of *M. campanuloides* at doses of 20 mg/kg/day and 40 mg/kg/day orally for 21 days, respectively. Serum TAC levels, follicles counts including primordial, primary, preantral, antral and atretic follicles, and PCNA expression in granulosa cells were evaluated. Numbers of preantral follicles increased in T 1 and T 2 groups compared to C group ( $P < 0.05$ ). TAC and numbers of preantral and antral follicles increased in T 2 group compared to T 1 and C groups ( $P < 0.05$ ). PCNA expression in granulosa cells was increased in T 2 group compared to T 1 and C groups ( $P < 0.01$ ). In conclusion, treatment with *M. campanuloides* had positive effects on antioxidant activity, follicular dynamics, and PCNA expression of granulosa cell in rats.

**Keywords:** Antioxidant, *Michauxia campanuloides*, ovarian, PCNA, rat.

*Corresponding Author:*

Serdal Kurt, Dicle University, Faculty of Veterinary Medicine, Department of Obstetrics and Gynecology, 21280, Diyarbakir, Turkey  
E-mail address: serdal.kurt@hotmail.com

Date of initial submission: 16-06-2020  
Date of revised submission: 18-01-2021  
Date of acceptance: 23-02-2021

## INTRODUCTION

Antioxidant substances are molecules that can reduce or prevent cellular damage caused by oxidant substances (Abuelo et al., 2015). Oxidant substances are classified as reactive nitrogen species and reactive oxygen species (ROS) (Zhong and Zhou, 2013) and are generated as a natural by-product during cell metabolism in the biological system (Puppel et al., 2015). Antioxidants are divided into two groups, endogenous and exogenous. Exogenous antioxidants are very important because of their roles on the production and structure of endogenous antioxidants (Sen and Chakraborty, 2011). If the production of oxidant substances exceeds the defense capacity of antioxidant substances, oxidative stress occurs (Puppel et al., 2015). Oxidant substances have detrimental effects on cellular structures such as lipid, DNA and protein. Therefore, they can lead to low fertility and infertility due to cell apoptosis, disruption of ovarian steroidogenesis mechanism and other pathological effects on reproductive tracts (Agarwal et al., 2005). Oxidant production increases due to the metabolic activity of granulosa cells during follicular development. Increased ROS production can cause granulosa cell degeneration, which leads to a decrease in ovulation rate and oocyte quality (Wang et al., 2017). Activations of cells are associated with DNA replications and the level of DNA replications can be observed by Proliferating Cell Nuclear Antigen (PCNA), a protein of DNA polymerase- $\delta$  enzymes required for DNA synthesis during replication (Strzalka and Ziemienowicz, 2011). PCNA is an important regulator of the cell cycle and has a role in DNA repair (Oktay et al., 1995; Tománek and Chronowska, 2006). PCNA expression increases in granulosa cells during follicular development (Oktay et al., 1995). Exogenous antioxidant supplements have positive effects on ovarian follicular dynamics and cell activities (Zhong and Zhou, 2013). Plants are one of the most important natural sources of exogenous antioxidants (Luximon-Ramma et al., 2002). In addition, antioxidant substances can be synthetically produced (Sen and Chakraborty, 2011). However, it was reported that many synthetic antioxidant substances can have toxic or mutagenic effects (Fejes et al., 1998; Sen et al., 2010; Al-Amiery et al., 2012; Čilerdžić et al., 2013). Therefore, natural plant origin antioxidants are better than synthetic antioxidants (Sen et al., 2010; Zhong and Zhou, 2013). There are many plants containing antioxidants (Krishnaiah et al., 2007; Čilerdžić et al., 2013; Zhong and Zhou, 2013; Hamidpour et al., 2017). *Michauxia campanu-*

*loides* L'Hér. (Campanulaceae) is one of the antioxidants containing plants (Hürkul and Köroğlu, 2019; Koca et al., 2020). *M. campanuloides* grows naturally in Mersin (Turkey) province. Plants are biennial, 25-200 cm long, bodied, strong herbaceous. Also, its root or stem can be eaten after cooking or peeling and the leaves of *M. campanuloides* are used externally in traditional medicine, as wound healer by applying directly on the wound in Kahramanmaraş shire (Hürkul and Köroğlu, 2019; Damboldt, 1978; Güvenç et al., 2012). In previous study, the antioxidant activity and total phenolic contents of *M. campanuloides* was determined by various methods. The strongest antioxidant activity in 1,1-diphenyl-2-picrylhydrazyl (DPPH) of *M. campanuloides* was found in aqueous extract of its aboveground part (Güvenç et al., 2012).

The aim of this study was to investigate the effect of aqueous extract of aerial parts of *M. campanuloides* on PCNA expression in granulosa cells, ovarian histomorphology and total antioxidant capacity (TAC) in Wistar Albino female rats.

## MATERIALS AND METHODS

### Plant materials and extraction procedure

The plant, *M. Campanuloides*, material used in the study was collected from Mersin province (Turkey, 2010). A voucher specimen was deposited in the Ankara University Faculty of Pharmacy Herbarium (Herbarium number AEF 25892). 100 g of the powder of *M. Campanuloides* was boiled with 500 ml of distilled water for 30 minutes, filtered and lyophilized, and finally 12 g lyophilized extract was obtained. In the previous study, total contents of the phenolic compounds in the extract were determined by the Folin-Ciocalteu method as gallic acid equivalent. The total phenol content of the aqueous extract was found 107.3 mg equivalent to gallic acid per gram extract (Güvenç et al., 2012). Some results in the previous study on current extract are presented in the discussion section (Güvenç et al., 2012).

### Animal diets and management

18 female Wistar Albino rats (8 weeks old) weighing 170-220 g were used in this study. This study was approved by the Experimental Research Ethics Committee of Bingöl University (Bingöl University Ethical Council Number: 2019/02-01/04). In this protocol, there are no *in vitro* or other alternative methods that could prevent the use of animals for the ovarian histomorphology study. The use, numbers and man-

agement of animals in this study are in accordance with the European Community Guidelines of ethical use and care of lab animals (Directive 2010/63). The rats were obtained from the Experimental Research Center of Bingol University and were housed at 12 hours dark, 12 hours light and temperature of 23 °C with constant humidity. The animals were fed with a standard pellet diet and water ad libitum during the experimental period.

### Experimental design

The rats were randomly divided into three groups as control (C; n = 6), treatment 1 (T 1; n = 6) and treatment 2 (T 2; n = 6) groups. Then the rats were weighed and the adaptation process was performed for 7 days. No treatment was made, only daily checks were done during this period. The rats in the T 1 and T 2 groups were given aqueous extract of *M. campanuloides* at doses of 20 mg/kg/day and 40 mg/kg/day orally using a gavage for 21 days, respectively. The volume of aqueous extract administered to both groups was 1 ml per day. Similarly, rats in group C received the same volume of distilled water. The dose of extract of *M. campanuloides* was determined considering its proliferative effect on sperm concentration (Koca et al., 2020) and phenolic antioxidant level in the previous studies (Güvenç et al., 2012). In this protocol, the total phenol concentrations of the extract administered in T 1 and T 2 were 2.14 mg/kg and 4.29 mg/kg/day per rat, respectively.

### Sample collection and tissue preparation

All rats were anaesthetized by intramuscular administration of xylazine (Rompun®, Bioveta, Czech Republic) and ketamine (Ketasol®, Richterpharma ag, Austria) at the same timepoint of the study. Blood samples (2 ml) were collected from the tail vein into vacutainer tubes (Hema & Tube®, Italy) with clot activator. Immediately after this process and while being in general anesthesia, all rats were euthanized by decapitation (Van Rijn et al., 2011). The blood samples were centrifuged at 1500 g for 10 minutes and the serum samples were immediately stored at -80 °C until TAC analysis. Ovarian tissues were completely removed by making a ventral midline incision in all rats and one of ovaries of each rat was weighed. The other ones were rapidly frozen at -80 °C for further examinations. Immunohistochemistry studies were performed on frozen tissues according to the instructions of Shi et al. (2008). Before starting the study, these ovaries were thawed, fixed in 10% neutral buff-

ered formalin solution, dehydrated with ethanol series and clarified by using xylene. The fixed ovaries were embedded in paraffin blocks. Then serial sections of 5 µm thickness were obtained with a rotary microtome. A total of 7 sections were taken, leaving a distance of 45 µm between the sections. The first 6 slides were stained with hematoxylin and eosin (H & E), and used for follicle counting (Tománek and Chronowska, 2006). The 7th slides were immunohistochemically stained with PCNA antibody, and used to determine both PCNA index in granulosa cells (Strzalka and Ziemienowicz, 2011) and the number of follicles (Tománek and Chronowska, 2006).

### Measurement of total antioxidant capacity (TAC)

The serum TAC levels of each rat were measured by autoanalyser using commercial kits (LOT: OK18095A, Rel Assay Diagnostics, Gaziantep, Turkey).

### Follicle counting

The counting of ovarian follicles was manually performed under a light microscope at 200 magnification (Nikon H550L, Japan) by a blind observer. To avoid counting more than once the same follicles, the follicle was counted only when the nucleus was clearly identified (Rajaei et al., 2019). Primordial (single layer of flattened granulosa cells), primary (single layer of cuboidal granulosa cells), preantral (at least two layers of cuboidal granulosa cells, no antral cavity) and antral follicles (numerous layers of cuboidal granulosa cells with an antral cavity) were characterized according to granulosa cells and layers around the oocyte. If there are vacuolization in the follicles, pycnotic nuclei in granulosa cells and shrinkage in the oocyte, they were characterized as atretic follicles (Rajaei et al., 2019).

### PCNA immunohistochemistry

In this study, we investigated the PCNA index to determine the effect of treatment on granulosa cell viability between different experimental groups. For this purpose, sections of 5 µm taken from the ovarian tissues were passed through xylol and decreasing alcohol series and washed in phosphate buffer saline (PBS) for 3 X 5 minutes. The sections were heated in Citrate buffer (pH: 6.0) to remove antigen blockage and washed again 3 X 5 minutes in PBS. The sections were kept for 30 minutes in 3% H<sub>2</sub>O<sub>2</sub> prepared in methanol for endogenous peroxidase blockade and were washed again in PBS. After applying the

serum to the samples, PCNA antibody (Santa Cruz, sc-25280) prepared with 1/300 dilution was instilled on sections and left overnight at + 4 °C. After these procedures, secondary antibody and streptavidin peroxidase administrations were performed. These methods were conducted with UltraVision Large Volume Detection System according to the manufacturer's instructions (Thermo, Cat no: TP-125-HL). Then the sections were washed again in PBS and DAB chromogen (Thermo, TL-125-HD) was applied. The sections were examined under the microscope until it reacted with the DAB chromogen. When the reaction was observed, the sections were taken to PBS and counterstained with hematoxylin. Then they were kept for 5 minutes in increasing alcohol series and were passed from two xylol series for 15 minutes. Finally, the sections were covered with entellan and examined under a microscope.

PCNA positive granulosa cells were counted under the light microscope at 400 magnification (Nikon H550L, Japan) and microphotographs were captured with NIS elements software version 3.22 (Nikon, Japan) depending on whether the granulosa cells were DAB positive or negative. The expression of PCNA positive granulosa cells was evaluated for each follicle individually. The PCNA index was determined for all follicles (excluding atretic follicles) with or without nuclei.

### Statistical analysis

In the present study, the group sizes were determined as 6, according to the results of the power analysis using 80% power and 5% margin of error. All evaluated datasets were analysed statistically with SPSS version 24.0 (IBM, USA). Before the statistical analyses, the normality test was performed with Kolmogorov-Smirnov test. Primordial and preantral follicle counts, serum TAC levels and PCNA expression positive cell index data which were found to be normally distributed were evaluated by parametric One-Way Anova test. On primary, antral and atretic follicle counts were not found to be normally distributed, the Non-parametric Kruskal Wallis test was performed. In both statistical analyses, multiple comparisons were performed with the Post-hoc Tukey and the Tamhane's T 2 tests, respectively. P-value less than 0.05 was considered statistically significant. The results were shown as mean  $\pm$  standard error of the mean (SEM).

## RESULTS

### Serum TAC

Serum TAC level was higher significantly in T 2 group ( $0.87 \pm 0.14$  mmol/L) compared to T 1 ( $0.58 \pm 0.04$  mmol/L) and C ( $0.28 \pm 0.08$  mmol/L) groups ( $P < 0.05$ ).

### Ovary weight

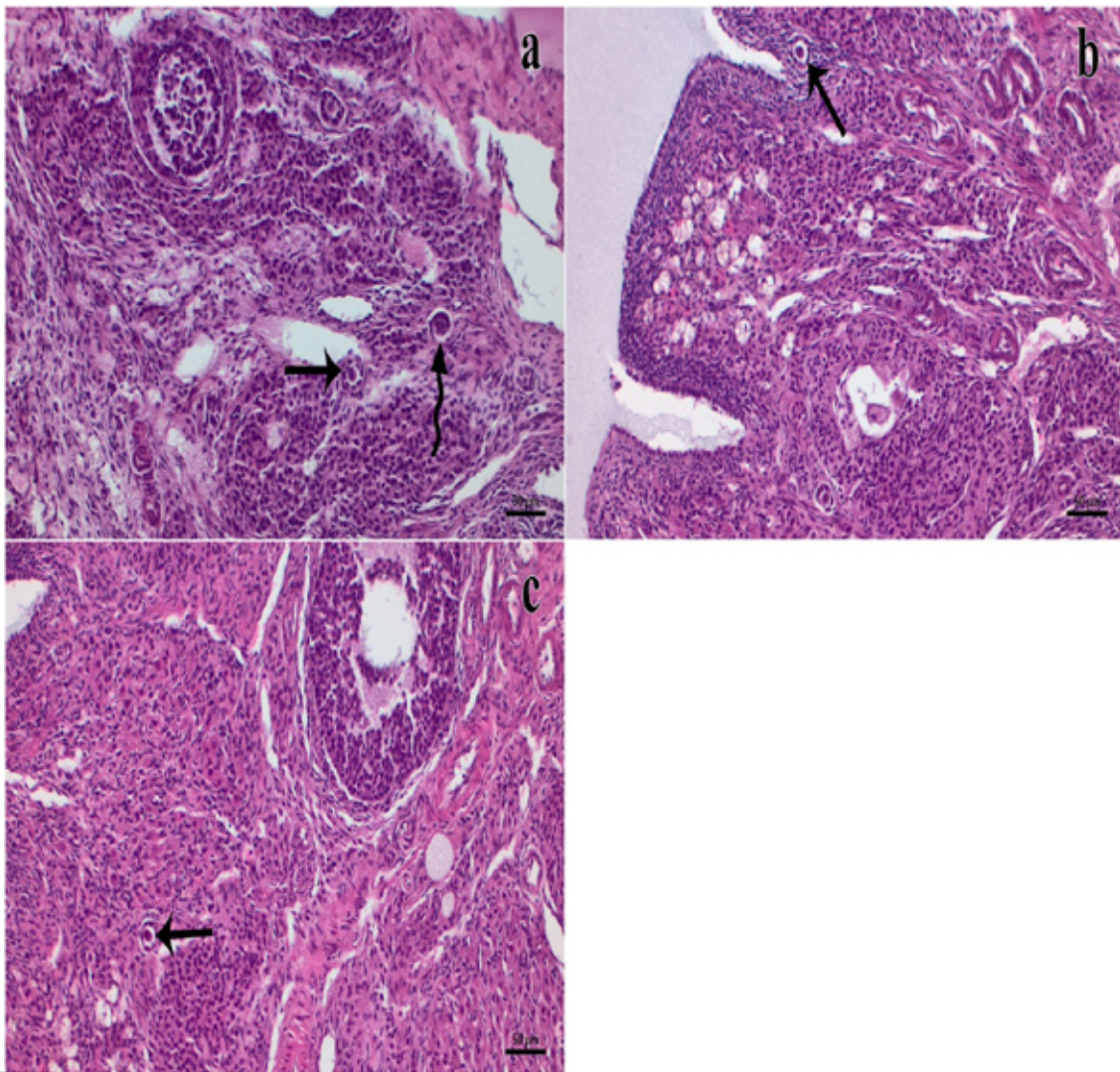
Treatment with *M. campanuloides* did not significantly affect ovary weights in the T 1 ( $0.06 \pm 0.01$  g), T 2 ( $0.06 \pm 0.01$  g) and C ( $0.06 \pm 0.01$  g) groups ( $P > 0.05$ ) (Figure 2).

### Ovarian histomorphology

In the ovarian tissue sections of the C, T 1 and T 2 groups, primordial, primary, preantral, antral and atretic follicles and corpus luteum presence were observed. No pathological finding was detected in the morphological examination (Figure 1). The numbers of preantral follicles increased significantly in T 1 and T 2 groups compared to C group ( $P < 0.05$ ). Antral follicles increased significantly in T 2 group compared to the other groups ( $P < 0.05$ ). However, there were no significant differences in the number of primordial, primary and atretic follicles in T 2 group compared to T 1 and C groups ( $P > 0.05$ ). Besides, no statistical difference was observed in any follicle types when T 1 group was compared to C group ( $P > 0.05$ ). The follicle count results are presented in Table 1.

### Immunohistochemistry

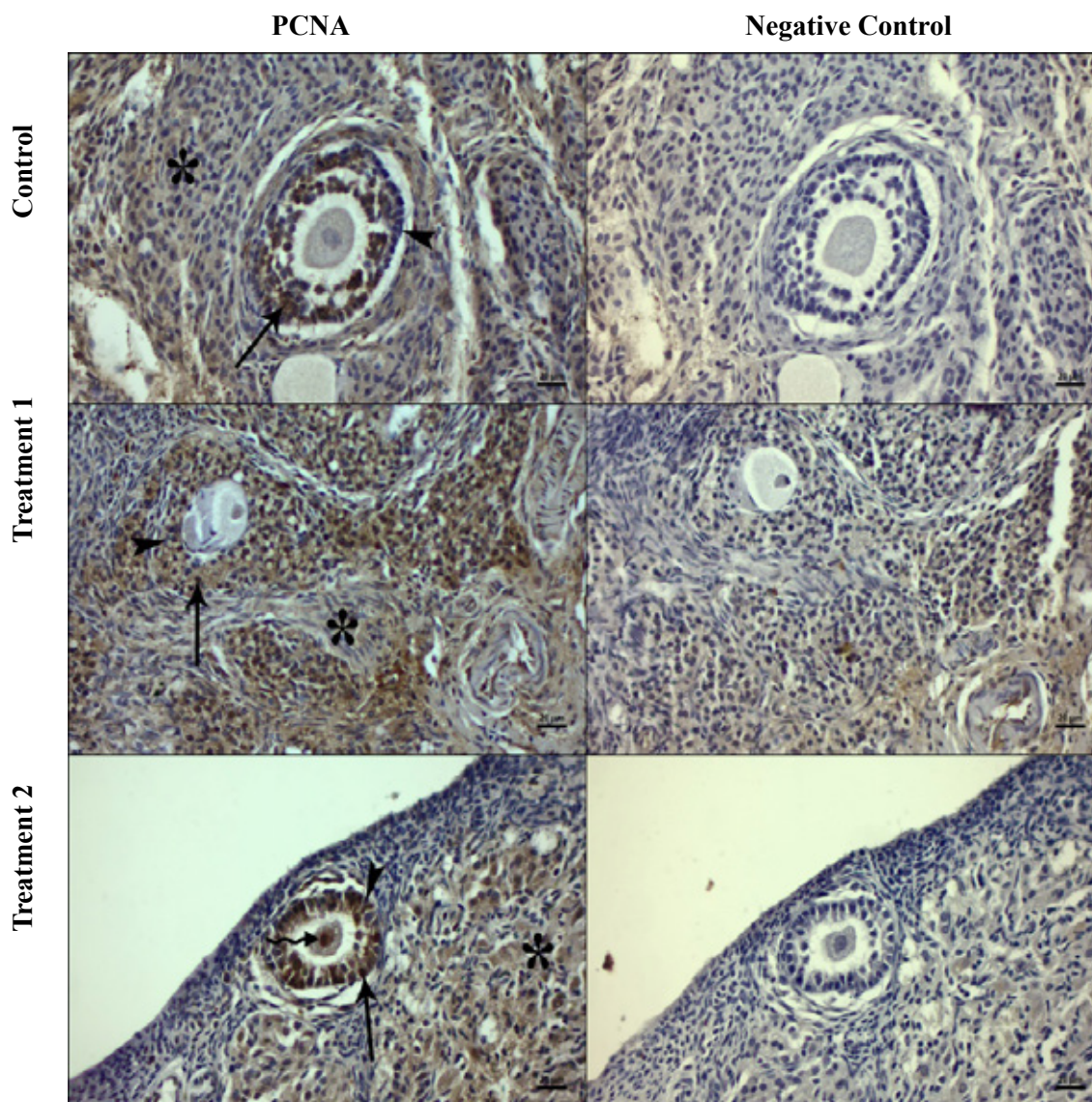
Distribution of nuclear positive and negative signals in granulosa cells was observed in ovarian sections of all groups. Weak positive signals were observed in interstitial cells and ovarian capillaries endothelium. When the positive signals were compared with negative control signals of interstitial cells and ovarian capillaries endothelium, it was found to have a similar distribution. However, DAB positivity was not seen in negative control samples of granulosa cells (Figure 2). Immunohistochemically, PCNA expression positive granulosa cells index increased significantly in T 2 group ( $64.98 \pm 1.67$  %) compared to T 1 ( $60.45 \pm 1.47$  %) and C ( $55.87 \pm 1.87$  %) groups ( $P < 0.01$ ). At the same time, although there was a numerical increase in PCNA expression of T 1 group compared to C group, no statistical difference was found between these groups ( $P > 0.05$ ) (Figure 6).



**Figure 1:** H & E microphotographs of the groups. a: Control, b: Treatment 1, c: Treatment 2. The microphotographs show developing (arrow) and atretic (curved arrow) follicles. Staining: H & E. Bar: 100 µm.

**Table 1.** Comparison of the number (Mean  $\pm$  SEM) of primordial, primary, preantral, antral and atretic follicles in Control, Treatment 1 and Treatment 2 rats. Different superscript at the same line indicates the statistical difference.

Follicles	Control	Treatment 1	Treatment 2	P
<b>Primordial</b>	13.17 $\pm$ 1.42 <sup>a</sup>	14.00 $\pm$ 0.58 <sup>a</sup>	14.00 $\pm$ 0.73 <sup>a</sup>	>0.05
<b>Primary</b>	5.17 $\pm$ 0.54 <sup>b</sup>	6.17 $\pm$ 0.17 <sup>b</sup>	6.50 $\pm$ 0.43 <sup>b</sup>	>0.05
<b>Preantral</b>	4.17 $\pm$ 0.40 <sup>c</sup>	6.67 $\pm$ 0.92 <sup>d</sup>	7.67 $\pm$ 0.56 <sup>d</sup>	<0.05
<b>Antral</b>	3.67 $\pm$ 0.33 <sup>e</sup>	3.50 $\pm$ 0.22 <sup>e</sup>	5.50 $\pm$ 0.34 <sup>f</sup>	<0.05
<b>Atretic</b>	3.50 $\pm$ 0.43 <sup>g</sup>	3.00 $\pm$ 0.45 <sup>g</sup>	2.17 $\pm$ 0.31 <sup>g</sup>	>0.05



**Figure 2:** PCNA microphotographs of the groups. The microphotographs show positive (arrow) and negative (arrowhead) signals in granulosa cells of preantral follicles, weak nuclear positivity in interstitial cells (\*) and positive signal in the oocyte of treatment 2 group (curved arrow). Staining: PCNA immunohistochemistry, Bar: 20  $\mu$ m.

## DISCUSSION

It was reported that plants containing phenolic compound have strong antioxidant properties and exhibit high antioxidant activity (Asif, 2015). *M. campanuloides* extract has an antioxidant property with phenolic content (Hürkul and Köroğlu, 2019). In the previous study conducted on the current extract, the highest antioxidant content of *M. campanuloides* was observed in the ethanolic extract,  $439.05 \pm 18.70$  mg/g as gallic acid equivalents. The half-maximal inhibitory concentrations ( $IC_{50}$ ) value of the aqueous extract in the thiobarbituric acid test for antioxidant activity was found  $464.98 \pm 2.21$  mg/ml. On the other hand, its the strongest antioxidant activity in DPPH was found in aqueous extract (Güvenç et al., 2012). It

has been observed that its antioxidant activity changes according to the extract type. In the present study, we used aqueous extract because of its powerful antioxidant activity. Besides, a recent study demonstrated that aqueous extract of *M. campanuloides* improved some semen parameters in rats (Koca et al., 2020).

Khaki et al. (2009) have reported that antioxidant containing plant significantly increased the level of TAC in rats. In our study, TAC levels were similar in C and T 1 groups. However, a significant increase in TAC levels was observed in T 2 group compared to the other groups. It was determined that the dose of administration had an effect on TAC levels. However, the antioxidant concentrations may have been

partially metabolized by combating ROS in treatment groups. Therefore, it is thought that measuring serum oxidant level is important in antioxidant studies. However, oxidant levels were not measured in this study because our primary aim was to investigate its antioxidant effect in rats. Antioxidant substances have a beneficial effect on energy metabolism (Maritim et al., 2003) and can have an effect on ovarian tissue mass (Chuffa et al., 2011). However, several researchers reported that treatment with antioxidant had no effect on ovary weight (Rajaei et al., 2019; Soleymani et al., 2010). Similarly, in our study, no significant difference was observed between the groups in terms of ovarian weights ( $P > 0.05$ ).

It was reported that administrations of plant extract containing antioxidant increased the numbers of follicles and follicular activity in animals (Zhong and Zhou, 2013). Besides, it was declared that animals with low fertility have insufficient antioxidant capacity (Stier et al., 2012). Some researchers showed that antioxidant agents improved folliculogenesis (Soleymani et al., 2010). Abdollahifar et al. (2019) reported that antioxidant has a positive effect on the total number of primordial, primary and antral follicles in mice. In the presented study, a significant increase in the number of antral (T 2) and preantral (T 1 and T 2) follicles was observed. So, it is understood that *M. campanuloides* has a beneficial effect on developed follicles. However, it did not affect the numbers of primordial and primary follicles. When these results are considered, it is concluded that it did not affect the emergence of new follicles from the follicular pool of the ovary.

During the development process of follicles, approximately 99% of them can be atresia (Sugino,

2005). It was noted that antioxidants have a protective effect against apoptosis in rat antral follicles cultured (Ciani et al., 2009). Yener et al. (2013) reported antioxidant administrations reduced atresia of antral follicles. Similarly, Özcan et al. (2015) reported that antioxidants have the effect of reducing follicular atresia. In the present study, we found that numbers of atretic follicles were similar between the groups. It was reported that PCNA expression increases during granulosa cell proliferation (Can et al., 2018). However, follicular atresia is associated with apoptosis of granulosa cells (Sugino, 2005), and PCNA expression gradually decreases with increased atresia (Can et al., 2018). In a previous study, it was indicated that antioxidants have positive effects on the functions of granulosa cells during folliculogenesis (Tománek and Chronowska, 2006). In our study, *M. campanuloides*, as an antioxidant agent, provided an effective improvement in PCNA expression in granulosa cells. However, it was observed that its positive effect on granulosa cells was associated with serum TAC levels because no significant differences were observed in PCNA expression between the T 1 and C groups. However, there was a significant increase in PCNA expression in the T 2 group compared to the other groups.

## CONCLUSION

Treatment with aqueous extract of *M. campanuloides* had a positive effect on antioxidant activity, follicular dynamics and PCNA expression of granulosa cell in female Wistar Albino rats. Despite the fact that the treatment dose caused differences on these results, it still evidenced its positive potential in the rat model. It is believed that multifaceted research will provide further information on the toxicological and pharmacological potential of *M. campanuloides*.



## REFERENCES

- Abdollahifar MA, Azad N, Sajadi E, Mofaraha ZS, Zare F, Moradi A, Rezaee F, Gholamin M, Abdi S (2019) Vitamin C restores ovarian follicular reservation in a Mouse model of aging. *Anatomy & Cell Biology* 52 (2) : 196-203.
- Abuelo A, Hernandez J, Benedito JL, Castillo C (2015) The importance of the oxidative status of dairy cattle in the periparturient period: revisiting antioxidant supplementation. *Journal of Animal Physiology and Animal Nutrition* 99 (6) : 1003-1016.
- Agarwal A, Gupta S, Sharma RK (2005) Role of oxidative stress in female reproduction. *Reproductive Biology and Endocrinology* 3 (1) : 28.
- Al-Amiery AA, Al-Bayati RI, Saour KY, Radi MF (2012) Cytotoxicity, antioxidant, and antimicrobial activities of novel 2-quinolone derivatives derived from coumarin. *Research on Chemical Intermediates* 38 (2) : 559-569.
- Asif M (2015) Chemistry and antioxidant activity of plants containing some phenolic compounds. *Chemistry International* 1 (1) : 35-52.
- Can B, Atilgan R, Pala S, Kuloğlu T, Kiray S, İlhan N (2018) Examination of the effect of ovarian radiation injury induced by hysterosalpingography on ovarian proliferating cell nuclear antigen and the radioprotective effect of amifostine: an experimental study. *Drug Design, Development and Therapy* 12: 1491–1500.
- Chuffa LGA, Amorim JPA, Teixeira GR, Mendes LO, Fioruci BA, Pinheiro PFF, Seiva FRF, Novelli ELB, Júnior WM, Martinez M, Martinez FE (2011) Long-term melatonin treatment reduces ovarian mass and enhances tissue antioxidant defenses during ovulation in the rat. *Brazilian Journal of Medical and Biological Research* 44 (3) : 217-223.
- Ciani F, Cocchia N, Angelo D, Tafuri S (2009) Influence of ROS on ovarian functions. In: Wu B, Editor. *New Discoveries in Embryology*. 1rd ed, UK, London: pp. 41-73.
- Čilerdžić J, Stajic M, Vukojević J, Duletic-Lausevic S (2013) Oxidative stress and species of genus *Ganoderma* (higher Basidiomycetes). *International Journal of Medicinal Mushrooms*, 15 (1) : 21-28
- Dai XX, Duan X, Cui XS, Kim NH, Xiong B, Sun SC (2015) Melamine induces oxidative stress in mouse ovary. *Plos one* 10 (11) : 1-9.
- Damboldt J (1978) *Campanulaceae*. In: Davis PH, Editor. *Flora of Turkey and the East Aegean Islands*. Vol. 6. 1rd ed, Edinburgh University Press, UK: Edingburg: pp. 2-64.
- Fejes S, Kery A, Blazovics A, Lugasi A, Lemberkovics E, Petri G, Szöke E (1998) Investigation of the in vitro antioxidant effect of *Petroselinum crispum* (Mill.) Nym. ex AW Hill. *Acta Pharmaceutica Hungarica* 68 (3) : 150-156.
- Güvenç A, Akkol EK, Hürkul MM, Süntar İ, Keleş H (2012) Wound healing and anti-inflammatory activities of the *Michauxia* L'Hérit (Campanulaceae) species native to Turkey. *Journal of Ethnopharmacology* 139 (2) : 401-408.
- Hamidpour R, Hamidpour S, Hamidpour M, Shahleri M, Sohraby M, Shahleri N, Hamidpour R (2017) Russian olive (*Elaeagnus angustifolia* L.) : From a variety of traditional medicinal applications to its novel roles as active antioxidant, anti-inflammatory, anti-mutagenic and analgesic agent. *Journal of traditional and complementary medicine* 7 (1) : 24-29.
- Hürkul MM, Köroğlu A (2019) A review on the ethnobotanical use, chemical content and biological activity of the campanulaceae family. *Türk Farmakope* 2019; 4 (3) : 70-84.
- Khaki A, Fathi AF, Ahmadi AHR, Rastgar H, Rezazadeh SA (2009) Effects of *Danae racemosa* on Spermatogenesis in Rat. *Journal of Medicinal Plants* 3 (31) : 87-92.
- Koca RH, Hürkul MM, Kurt S, Köroğlu A (2020) Wistar Albino Sıçanlarda *Michauxia campanuloides* L'Hér.'in Bazı Sperma Parametreleri Üzerine Etkisi. *Atatürk Üniversitesi Journal of Veterinary Science* 15 (2) : 138-144.
- Köroğlu A, Hürkul MM, Özbay Ö (2012) Antioxidant Capacity and Total Phenol Contents of *Bifora radians* Bieb. *FABAD Journal of Pharmaceutical Sciences* 37 (3) : 123.
- Krishnaiah D, Sarbatly R, Bono A (2007) Phytochemical antioxidants for health and medicine a move towards nature. *Biotechnology and Molecular Biology Reviews* 2 (4) : 97-104.
- Luximon-Ramma A, Bahorun T, Soobrattee MA, Aruoma OI (2002) Antioxidant activities of phenolic, proanthocyanidin, and flavonoid components in extracts of *Cassia fistula*. *Journal of Agricultural and Food Chemistry* 50 (18) : 5042-5047.
- Lykkefeldt J, Svendsen O (2007) Oxidants and antioxidants in disease: oxidative stress in farm animals. *The Veterinary Journal* 173 (3) : 502-511.
- Maritim A, Sanders A, Watkins IIIJ (2003) Diabetes, oxidative stress, and antioxidants: a review. *Journal of Biochemical and Molecular Toxicology* 17 (1) : 24-38.
- Oktay K, Schenken RS, Nelson JF (1995) Proliferating cell nuclear antigen marks the initiation of follicular growth in the rat. *Biology of reproduction* 53 (2) : 295-301.
- Özcan P, Fişciyoğlu C, Yıldırım ÖK, Özkan F, Akkaya H, Aslan İ (2015) Protective effect of resveratrol against oxidative damage to ovarian reserve in female Sprague–Dawley rats. *Reproductive Biomedicine Online* 31 (3) : 404-410.
- Puppel K, Kapusta A, Kuczyńska B (2015) The etiology of oxidative stress in the various species of animals, a review. *Journal of the Science of Food and Agriculture* 95 (11) : 2179-2184.
- Rajaei S, Alihemmati A, Abedelahi A (2019) Antioxidant effect of genistein on ovarian tissue morphology, oxidant and antioxidant activity in rats with induced polycystic ovary syndrome. *International Journal of Reproductive BioMedicine* 17 (1) : 1-12.
- Sen S, Chakraborty R (2011) The role of antioxidants in human health, oxidative stress: diagnostics, prevention, and therapy. *ACS Publications* 1083 (1) : 1-37.
- Sen S, Chakraborty R, Sridhar C, Reddy Y, De B (2010) Free radicals, antioxidants, diseases and phytomedicines: current status and future prospect. *International Journal of Pharmaceutical Sciences and Research* 3 (1) : 91-100.
- Shi SR, Liu C, Pootrakul L, Tang L, Young A, Chen R, Cote RJ, Taylor CR (2008) Evaluation of the value of frozen tissue section used as “gold standard” for immunohistochemistry. *American Journal of Clinical Pathology* 129 (3) : 358-366.
- Soleymani MM, Nourafshan A, Hamta A, Moumeni HR, Abnoui MH, Mahmoudi M, Anvari M, Hazaveh M (2010) Effects of vitamin E on ovarian tissue of rats following treatment with p-nonylphenol. *A Stereological Study*. *Iranian Journal of Reproductive Medicine*, 2010; 8 (1) : 1-9.
- Stier A, Reichert S, Massem S, Bize P, Criscuolo F (2012) Constraint and cost of oxidative stress on reproduction: correlative evidence in laboratory mice and review of the literature. *Frontiers in Zoology* 9 (1) : 37.
- Strzalka W, Ziemiencowicz A, (2011) Proliferating cell nuclear antigen (PCNA) : a key factor in DNA replication and cell cycle regulation. *Annals of Botany* 107 (7) : 1127-1140.
- Sugino N (2005) Reactive oxygen species in ovarian physiology. *Reproductive Medicine and Biology* 4 (1) : 31-44.
- Tománek M, Chronowska E (2006) Immunohistochemical localization of proliferating cell nuclear antigen (PCNA) in the pig ovary. *Folia Histochemica et Cytobiologica* 44 (4) : 269-274.
- Van Rijn CM, Krijnen H, Menting-Hermeling S, Coenen, AM (2011) Decapitation in rats: latency to unconsciousness and the ‘wave of death’. *Plos one* 6 (1) : 1-6.
- Wang S, He G, Chen M, Zuo T, Xu W, Liu X (2017) The role of antioxidant enzymes in the ovaries. *Oxidative Medicine and Cellular Longevity* (2017) : 1-14.
- Yener NA, Sinanoglu O, Ilter E, Celik A, Sezgin G, Midi A, Deveci U, Aksungar F (2013) Effects of spirulina on cyclophosphamide-induced ovarian toxicity in rats: biochemical and histomorphometric evaluation of the ovary. *Biochemistry Research International* (2013) : 1-7.
- Zhong RZ, Zhou DW (2013) Oxidative stress and role of natural plant derived antioxidants in animal reproduction. *Journal of Integrative Agriculture* 12 (10) : 1826-1838.