

See discussions, stats, and author profiles for this publication at: <https://www.researchgate.net/publication/330847707>

Künt travma sonrası total servikal rüptür

Article in *Tuberkuloz Ve Toraks* · December 2018

DOI: 10.5578/tt.67717

CITATIONS

0

READS

64

6 authors, including:



Ahmet Dumanli

Afyon Kocatepe University

26 PUBLICATIONS 47 CITATIONS

[SEE PROFILE](#)



Adem Gencer

Afyon Kocatepe University

9 PUBLICATIONS 33 CITATIONS

[SEE PROFILE](#)



Neşe nur User

Afyonkarahisar Health Sciences University

12 PUBLICATIONS 26 CITATIONS

[SEE PROFILE](#)



Abdulkadir Bucak

Afyon Health Sciences University

44 PUBLICATIONS 288 CITATIONS

[SEE PROFILE](#)

Some of the authors of this publication are also working on these related projects:



Comparison of Pulmonary Hydatid Cysts between Men and Women [View project](#)



Swyer-James syndrome or destroyed lung?/ Coronary artery bypass in a patient with Swyer-James syndrome due to pulmonary tuberculosis [View project](#)



doi • 10.5578/tt.67717
Tuberk Toraks 2018;66(4):345-348
Geliş Tarihi/Received: 20.12.2018 • Kabul Ediliş Tarihi/Accepted: 22.12.2018

OLGU SUNUMU
CASE REPORT

Total cervical tracheal rupture following blunt trauma

Ahmet DUMANLI¹
Adem GENCER¹
Neşe Nur USER²
Abdulkadir BUCAK³
Ersin GÜNAY⁴
Gürhan ÖZ¹

¹Department of Chest Surgery, Faculty of Medicine, Afyonkarahisar Health Sciences University, Afyonkarahisar, Turkey

¹ Afyonkarahisar Sağlık Bilimleri Üniversitesi Tıp Fakültesi, Göğüs Cerrahisi Anabilim Dalı, Afyonkarahisar, Türkiye

² Department of Emergency Medicine, Faculty of Medicine, Afyonkarahisar Health Sciences University, Afyonkarahisar, Turkey

² Afyonkarahisar Sağlık Bilimleri Üniversitesi Tıp Fakültesi, Acil Tıp Anabilim Dalı, Afyonkarahisar, Türkiye

³ Department of Otorhinolaryngology, Faculty of Medicine, Afyonkarahisar Health Sciences University, Afyonkarahisar, Turkey

³ Afyonkarahisar Sağlık Bilimleri Üniversitesi Tıp Fakültesi, Kulak Burun Boğaz Anabilim Dalı, Afyonkarahisar, Türkiye

⁴ Department of Chest Diseases, Faculty of Medicine, Afyonkarahisar Health Sciences University, Afyonkarahisar, Turkey

⁴ Afyonkarahisar Sağlık Bilimleri Üniversitesi Tıp Fakültesi, Göğüs Hastalıkları Anabilim Dalı, Afyonkarahisar, Türkiye

ABSTRACT

Total cervical tracheal rupture following blunt trauma

Tracheal ruptures are rarely seen and potentially high life-threatening injuries. Cervical tracheal injuries occur due to the penetrant trauma rather than the blunt trauma. On the other hand, total cervical tracheal rupture due to the blunt trauma is so rare. A 32 year-old male patient was admitted to the emergency service with complaints of breathlessness and stridor resulting from a traffic accident. Thorax computed tomography of the patient revealed total cervical tracheal rupture under the cricoid cartilage level. Emergency tracheostomy was opened and distal airway safety was provided in operating room. The patient underwent an anastomosis with Collar's incision and was discharged in 16th days postoperatively without any complication other than hoarseness.

Key words: Bronchoscopy; Collar's incision; tracheal rupture; blunt trauma; traffic accident

ÖZET

Künt travma sonrası total servikal rüptür

Trakeal rüptürler nadir görülen ve potansiyel olarak yaşamı tehdit eden yaralanmalardır. Servikal trakeal yaralanmalar künt travmadan ziyade penetran travmalara bağlı gelişir. Diğer taraftan, künt travmalara bağlı total servikal trakeal rüptür çok nadirdir. Otuz iki yaşında erkek hasta acil servise trafik kazası sonucunda oluşan nefes darlığı ve stridor yakınması ile getirildi. Hastanın toraks bilgisayarlı tomografisinde krikoid kırık seviyesinin altında total servikal trakeal rüptür saptandı. Hava yolu güvenliğinin sağlanması için ameliyathane koşullarında acil trakeostomi açıldı. Hastaya Collar insizyonu ile trakea anastomozu yapıldı. Postoperatif 16. günde ses kısıklığı dışında herhangi bir komplikasyon gözlenmeyen hasta taburcu edildi.

Anahtar kelimeler: Bronkoskopi; Collar's insizyonu; trakeal rüptür; künt travma; trafik kazası

Yazışma Adresi (Address for Correspondence)

Dr. Ersin GÜNAY
Afyon Kocatepe Üniversitesi Tıp Fakültesi,
Göğüs Hastalıkları Anabilim Dalı,
AFYONKARAHİSAR - TÜRKİYE
e-mail: ersingunay@gmail.com

Thirty-two year-old male patient was admitted to the emergency service with complaints of breathlessness and stridor resulting from traffic accident. He was referred to our clinic for suspected rupture of the trachea in the neck region observed on the neck and thorax computed tomography. Physical examination of the patient was as follows; general condition was poor, his consciousness was cloudy and he had had respiratory distress. Approximately 10 cm of ecchymosis was observed on the neck just below the thyroid cartilage (Figure 1A). Arterial oxygen saturation was 88%, pulse rate was 105 bpm, and blood pressure was 95/70 mmHg. Computed tomography of thorax and neck region showed total tracheal rupture immediately below the cricoid cartilage, subcutaneous emphysema, pneumomediastinum and minimal pneumothorax (Figure 1B). The patient, who had severe respiratory distress, was urgently taken to the

operating room. Emergency fiberoptic bronchoscopy (FOB) was applied for guidance of intubation and to demonstrate the characteristics of the rupture of the proximal end of the trachea in the operating room FOB revealed a total rupture of the trachea at the 3 cm distal to the vocal cord level. However, distal end of the trachea was not observed properly. Emergency tracheostomy and intubation was performed to obtain secure airway (Figure 1C). Collar's incision was made. At the exposition, it was found that the cervical trachea was totally separated just below the cricoid cartilage similar to the bronchoscopy examination. The trachea was repaired with end to end anastomosis. Perioperative complications were not observed unless hoarseness. Postoperatively, at 14th day, control FOB was performed. Bilateral vocal cord paralysis was observed. The tracheal lumen was open and the anastomosis line was intact (Figure 1D).

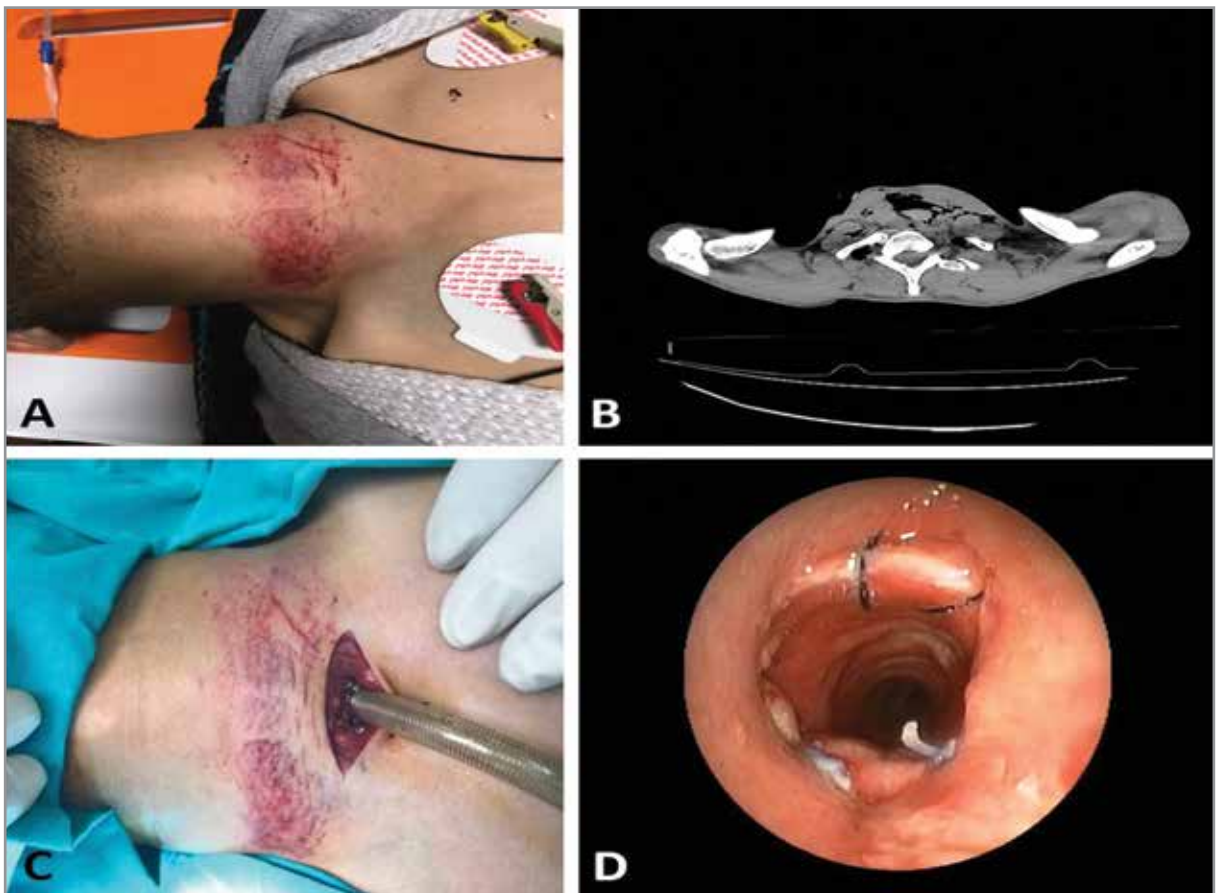


Figure 1. (A) Ecchymosis of the neck region due to blunt trauma, (B) Thorax computed tomography revealed a total rupture of the trachea and subcutaneous emphysema at the level of cervical vertebrae, (C) Tracheostomy was performed and secure airway was obtained, (D) Fiberoptic bronchoscopy of the patient at the 14th day of operation showed an open and patent airway with an anastomosis line around the trachea.

DISCUSSION

The incidence of tracheobronchial injuries in thoracic traumas is not known exactly, but varies between 1-4% (2). While penetrating tracheal injuries are mostly in the cervical region, blunt injuries frequently occur in the distal trachea and the main bronchi. Although our case was blunt trauma, the injured area was located in the cervical region.

Penetrating cervical tracheal injuries may be associated with damage to important structures such as esophagus, carotid arteries, jugular veins, pharynx, spinal cord, and recurrent laryngeal nerve. Blunt cervical tracheal injuries can also be associated with abdominal, orthopedic or head trauma. Therefore, detailed physical examination has a vital importance. (3,4) Our patient had total cervical rupture and bilateral recurrent laryngeal nerve injury.

The trachea and bronchi are composed of smooth muscles and mucous membranes supported by cartilages, tension pressures were low. So, tracheobronchial structures were susceptible to the trauma. 80% of tracheobronchial injuries occurring after blunt traumas occur around 2.5 cm of the main carina (5). In this case report, the injury type was a total cervical tracheal rupture just below the cricoid cartilage. The most common mechanism in blunt cervical tracheal injuries is the tightening of the trachea between the steering wheel and the vertebral column that resulting in the separation and dislocation of the trachea (6). Considering the ecchymotic area on the neck of our case report, it was thought that the trachea was trapped between the steering wheel and the vertebral column.

Findings after tracheobronchial injury may be very specific or ambiguous. The most common findings on physical examination are respiratory distress and subcutaneous emphysema but it can be many symptoms, including pneumothorax, hemoptysis, mediastinal emphysema.

The findings may be much more ambiguous in cases where the tracheal bronchial rupture is too small (2). Rapid diagnosis and adequate airway delivery is very important in tracheobronchial injuries. Computed tomography of the thorax has critical prognostic importance in assessing the presence of injury in the mediastinal other structures. Computed tomography of the thorax and neck region of our patient revealed the totally separated cervical trachea under cricoid

cartilage and extensive subcutaneous emphysema.

Flexible bronchoscopy is the gold standard method of introducing a tracheobronchial injury and helps operator to guide intubation to get a secure airway in case of total rupture (7).

Conservative management can be tried in patients with stable overall condition and small tracheal tears. However, the main treatment for tracheobronchial injuries is surgical repair. In primary repair, polypropylene and polydioxanone suture materials are generally preferred. In our case, tracheal anastomosis was performed with 3-0 polypropylene suture.

There may not be enough time for bronchoscopy in patients with severe respiratory distress (7-9). In the present case report, emergency bronchoscopy examination was performed in the operating room to guide intubation and to get a secure airway. Unfortunately, distal end of the trachea was not observed because of the total rupture. So, distal tracheal tracheostomy was opened and distal airway safety was obtained. Subsequent tracheal repair was performed with end to end anastomosis of the trachea.

CONCLUSION

In conclusion, blunt cervical tracheal ruptures are so rare. Computerized tomography of the neck and trachea is very helpful in diagnosis and localization of the tracheobronchial injuries and observing the presence of additional pathology. Fiberoptic bronchoscopic examination helps to guide intubation and to examine the level and the characteristics of the rupture. In an unstable patient, airway safety and intubation with tracheotomy must be obtained, and then surgical treatment should be planned according to the level of tracheal rupture.

REFERENCES

1. Kaptanoğlu M, Nadir A, Erbaş E, Gönügür U, Seyfikli Z, Doğan K, et al. *Trakeobronşiyal yaralanmalar: 15 olguluk bir serinin değerlendirilmesi. Turk Thorac J* 2001;2:54-9.
2. Altınok T, Can A. *Management of tracheobronchial injuries. Eurasian J Med* 2014;46: 209-15.
3. Ishibashi H, Ohta S, Hirose M, Akimoto T. *Blunt tracheal transection and long tear in posterior membranous trachea. Eur J Cardiothorac Surg* 2006;30:945-7.
4. Kelly JP, Webb WR, Moulder PV, Everson C, Burch BH, Lindsey ES, et al. *Management of airway trauma. I: tracheobronchial injuries. Ann Thorac Surg* 1985;40:551-5.

5. *Reece GP, Shatney CH. Blunt injuries of the cervical trachea: review of 51 patients. South Med J 1988;81:1542-8.*
6. *Johnson SB. Tracheobronchial injury. Semin Thorac Cardiovasc Surg 2008;20:52-7.*
7. *Mohammed S, Biyani G, Bhatia PK, Chauhan DS. Airway management in a patient with blunt trauma neck: A concern for anesthesiologist. Egyptian J Anesth 2014;30:431-3.*
8. *Lupetin AR. Computed tomographic evaluation of laryngotracheal trauma. Curr Probl Diagn Radiol 1997;26:185-206.*
9. *Richardson JD. Outcome of tracheobronchial injuries: along-term perspective. J Trauma 2004;56:30-6.*