

## Management of endovascular treatment in spontaneous iliac artery dissections: Applications enabling classical surgery

*Spontan İliyak arter diseksiyonlarında endovasküler tedavi yönetimi: Klasik cerrahiye olanak sağlayan uygulamalar*

Fehim Can Sevil<sup>1</sup>, Mehmet Tort<sup>1</sup>

Department of Cardiovascular Surgery, Erzurum Regional Education and Research Hospital, Erzurum, Turkey

### ABSTRACT

**Background:** This study aims to investigate the effectiveness of endovascular applications for the treatment of spontaneous iliac artery dissections.

**Methods:** The medical records of 13 patients (12 males, 1 female; mean age 67.9±5.7 years; range, 58 to 75 years) with spontaneous iliac artery dissection between January 2017 and December 2019 were retrospectively reviewed. The diagnosis of spontaneous iliac artery dissection was made based on contrast-enhanced computed tomography. Demographic and clinical characteristics of the patients, physical examination and imaging findings, and hybrid treatments applied during endovascular treatment were analyzed.

**Results:** The mean follow-up was 12.5±1.1 (range, 6 to 16) months. Five patients received hybrid treatment during endovascular treatment. The re-entry site was closed by a patch plasty over the common femoral artery in one of these patients. Embolectomy was performed in the remaining four patients for the treatment of acute ischemia of the extremities. Since no patency could be achieved in two of the patients undergoing embolectomy, a femoropopliteal bypass was performed. The technical success and primary patency rates were 100%. No new false lumen formation, intra-stent occlusion or arterial occlusion was observed during the hospital stay and follow-up.

**Conclusion:** Endovascular methods can be safely used in the treatment of spontaneous iliac artery dissections; however, hybrid treatments may be also required in selected cases. We believe that it is effective and safe to apply endovascular and hybrid treatments without preventing possible surgical treatments which may be required in the future.

**Keywords:** Dissection, endovascular treatment, hybrid treatment, iliac artery.

### ÖZ

**Amaç:** Bu çalışmada spontan iliyak arter diseksiyonlarının tedavisinde endovasküler uygulamaların etkinliği araştırıldı.

**Çalışma planı:** Ocak 2017 - Aralık 2019 tarihleri arasında spontan iliyak arter diseksiyonlu 13 hastanın (12 erkek, 1 kadın; ort. yaş 67.9±5.7 yıl; dağılım, 58-75 yıl) tıbbi kayıtları retrospektif olarak incelendi. Spontan iliyak arter diseksiyonunun tanısı, kontrastlı bilgisayarlı tomografi ile konuldu. Hastaların demografik ve klinik özellikleri, fizik muayene ve görüntüleme bulguları ve endovasküler tedavi sırasında uygulanan hibrit tedaviler incelendi.

**Bulgular:** Ortalama takip süresi, 12.5±1.1 (dağılım, 6-16) ay idi. Endovasküler tedavi sırasında beş hastaya hibrit tedavi uygulandı. Bu hastalardan birinde ana femoral artere yama plasti yapılarak, yeniden giriş bölgesi kapatıldı. Geri kalan dört hastada akut ekstremitte iskemisinin tedavisi amacıyla embolektomi uygulandı. Embolektomi uygulanan hastalardan ikisinde açıklık sağlanamaması nedeniyle, femoropopliteal baypas uygulandı. Teknik başarı ve primer açıklık oranları %100 idi. Hastanede yatış ve takip süresince yeni yalancı lümen oluşumu, stent içi oklüzyon veya arteriyel oklüzyon izlenmedi.

**Sonuç:** Spontan iliyak arter diseksiyonlarının tedavisinde endovasküler yöntemler güvenli bir şekilde kullanılabilir; ancak belirli olgularda hibrit tedaviler de gerekebilmektedir. Yapılacak endovasküler ve hibrit tedavilerin ileride gerekebilecek muhtemel cerrahi tedavileri engellemeyecek şekilde uygulanmasının etkili ve güvenilir olduğu kanaatindeyiz.

**Anahtar sözcükler:** Diseksiyon, endovasküler tedavi, hibrit tedavi, iliyak arter.

Received: March 16, 2020 Accepted: June 07, 2020 Published online: October 21, 2020

**Correspondence:** Fehim Can Sevil, MD. Afyonkarahisar Sağlık Bilimleri Üniversitesi, Kalp ve Damar Cerrahisi Anabilim Dalı, 03030 Afyonkarahisar, Türkiye.  
Tel: +90 541 - 620 02 32 e-mail: fhm\_can@hotmail.com

### Cite this article as:

Sevil FC, Tort M. Management of endovascular treatment in spontaneous iliac artery dissections: Applications enabling classical surgery. Turk Gogus Kalp Dama 2020;28(4):601-608

©2020 All right reserved by the Turkish Society of Cardiovascular Surgery.

This is an open access article under the terms of the Creative Commons Attribution-NonCommercial License, which permits use, distribution and reproduction in any medium, provided the original work is properly cited and is not used for commercial purposes (<http://creativecommons.org/licenses/by-nc/4.0/>).

Cases of isolated dissections of the iliac arteries without aortic involvement are extremely rare, but potentially catastrophic due to the possibility of rupture. Although the exact cause is still unclear, trauma, intense athletic events, pregnancy, connective tissue disease, iliac catheterization, and atherosclerosis have been shown as causative factors in the few cases reported in the literature.<sup>[1-5]</sup> Conservative treatment, classical surgical treatment, and endovascular treatment are among the options for the treatment of spontaneous iliac artery dissection (SIAD) without any established consensus.<sup>[2-6]</sup> Recent developments have enabled endovascular methods as the first-line treatment. Endovascular methods are procedures which do not require open surgical intervention and the procedure is completed in the angiography unit. In hybrid techniques, endovascular procedures are combined with surgical interventions and the targeted procedures for complete revascularization are aimed.<sup>[7]</sup> Discussions about the selection of stents are ongoing and the five-year stent patency rates have been reported as about 75% in previous studies.<sup>[7,8]</sup> Therefore, applications which do not prevent alternative treatments have gained importance such as classical surgery, when an occlusion occurs after an endovascular treatment.

In the present study, we aimed to investigate the application of endovascular treatment for SIAD without hindering surgical methods that might be required in the future and to examine the effectiveness of endovascular treatments performed in our center.

## PATIENTS AND METHODS

The medical records of 13 patients (12 males, 1 female; mean age  $67.9 \pm 5.7$  years; range, 58 to 75 years) with SIAD between January 2017 and December 2019 were retrospectively reviewed. All patients with SIAD proven by contrast-enhanced computed tomography (CT) were included in the study. Patients with a previous iliac artery surgery or any treatment for aortic dissection or occlusion, Leriche syndrome or abdominal aortic or iliac artery aneurysm were excluded from the study. All patients were treated at a single center by the same surgical team. The data collected included the demographics, symptoms on admission, physical examination results of the vascular system, comorbidities, findings of imaging studies, operation data and outcomes of the patients using the hospital database and patient files. The primary outcome measure of the study was primary patency rates during post-procedural follow-up. Primary patency was defined as an uninterrupted patency in the vessel

undergoing endovascular treatment. Technical success was defined as <30% residual stenosis following the procedure.

A written informed consent was obtained from each patient. The study protocol was approved by the Erzurum Regional Education and Research Hospital Ethics Committee (Date: 02.03.2020, No: 2020/05-57). The study was conducted in accordance with the principles of the Declaration of Helsinki.

## Pre-procedural planning and indications

The ankle-brachial index (ABI) was used for the vascular examination of the lower extremity in all patients. Lower extremity ischemia was defined as presence of any of the 5P symptoms including pulseless, pain, pale, paresthesia and paralysis, while lower extremity necrosis was defined as tissue death in any area of the lower extremity. All applications were planned based on contrast-enhanced CT data which provided a detailed assessment of the vascular structure. The CT interpretation focused on the degree of luminal stenosis, the entry and re-entry points of the dissection, whether the dissection extended to the internal iliac artery and to the common femoral artery, and the patency characteristics in the arterial structures distal to the common femoral artery.

The percentage of compression of the arterial lumen was measured using the unaffected iliac artery diameter and the diameter of the true lumen at the maximal stenotic region. True stenosis of the lumen was classified as stenosis between 25% and 50% and  $\geq 50\%$ .<sup>[9]</sup> The planned stent size to be implanted was determined by considering the native diameter of artery to be treated. In ineligible cases, the stent size was determined as maximum 10% above the diameter of the contralateral patent artery.

## Technique

Vascular access in endovascular treatment of SIAD can be established with an ipsilateral retrograde or contralateral approach. We established vascular access with an ipsilateral retrograde approach, since the downward passage from the distal aorta to the iliac artery was considered risky in the contralateral approach due to the aortic wall structure and anatomical structure.

All procedures were performed in the hybrid operating room. Contralateral retrograde femoral access was provided by ultrasonography guidance. A 5F sheath was inserted and 5,000 IU unfractionated heparin was applied intravenously. A pigtail catheter was inserted through a contralateral femoral access

for imaging purposes. The dissected segment was passed by a percutaneous guidewire in patients in whom no hybrid treatment was planned. The common femoral artery was explored at the beginning of the procedure in patients scheduled for hybrid treatment according to the result of preoperative CT evaluation. The sheath inserted for ipsilateral retrograde access was placed in the true lumen detected after arteriotomy. Stent diameters planned to be applied were determined by comparing the images taken with the pigtail inserted contralaterally and CT images taken before the procedure.

The internal structure of the graft covered stents we use is made of nitinol, and its inner surface and outer surface are covered with polytetrafluoroethylene. The stent is impregnated with carbon on the inner surface of the graft, and the distal and proximal of the stents facilitate attachment to the vessel wall. The guidewires to pass the dissected iliac artery section are soft tipped, hydrophilic coated on nitinol, and have a high maneuverability that makes them slippery when in contact with tissues such as water and blood. The balloon angioplasty dilators we use are balloons with paclitaxel release, safe to break, reaching a diameter of 5.97 mm with a pressure of 6 atm and a diameter of 6.66 mm with a pressure of 16 atm.

A balloon-expandable covered stent (Fluency™ Plus; Bard Peripheral Vascular Inc., AZ, USA) was first applied by an ipsilateral retrograde approach under imaging guidance to clear the segment for stent placement at the proximal part of the vessel, and the entry site was closed in cases with an isolated common iliac artery dissection with no extension to the external iliac artery. The procedure was terminated, when the false lumen was detected to be closed in conventional angiography performed after covered stent application. A self-expandable stent (iVolution™; iVascular S.L.U., Barcelona, Spain) was overlapped into the previous stent to close the re-entry site in the dissections with a continuing false lumen patency after the application.

A balloon-expandable covered stent was first applied with an ipsilateral retrograde approach to clear the segment for stent placement proximal to the vessel, and the entry site was closed in the cases without common iliac artery dissection, but with isolated external iliac artery dissection. A self-expandable stent was overlapped into the previous covered stent to close the re-entry site in the dissections with a continuing false lumen patency after the application. The stents were not extended to the common femoral artery in any of the endovascular procedures. Images were

taken using the contralaterally placed pigtail catheter after the application, and intra-stent balloon (iVascular S.L.U., Barcelona, Spain) was applied in the event of leakage.

A self-expandable stent was placed to overlap a minimum of 5 cm with the covered stent, while the covered stent was applied to the entry site in the common iliac artery in SIADs with common iliac artery dissection extending to the external iliac artery. The iliac stent was not extended to the common femoral artery not to cover the distal anastomosis site of the aortofemoral bypass which might be required in the future in cases in which the distal end of the stent applied in the external iliac artery was thought to extend in the common femoral artery. In these patients, the distal end of the stent was left proximal to the common femoral artery and surgical repair was performed on the common femoral artery.

The procedure was performed after applying covered stents to the iliac arteries in cases in which surgical intervention to the common femoral artery was required. Common femoral artery repair was provided by surgical methods in cases with the dissection extending to the common femoral artery and presence of re-entry site in this area. After the arteriotomy of the common femoral artery, dissection layers were fixed with the sutures placed through the arterial lumen, and the arteriotomy was closed with patch plasty using a patch graft. Distal embolectomy was performed in cases with SIAD and with ipsilateral common femoral artery occlusion. When no blood flow was achieved with this technique, vascularity of the extremity was ensured by a bypass procedure between the femoral artery and popliteal artery above the knee provided that the popliteal artery was deemed appropriate for this procedure by conventional angiography.

After the procedure, acetylsalicylic acid (100 mg daily) and clopidogrel (75 mg daily) were administered in all patients and the treatment was continued for a total of six months.

### Follow-up

In the follow-up protocol, post-procedural evaluation of the patients was performed by the ABI and Duplex ultrasonography in the outpatient setting. Stent positions and patency rates were evaluated using Duplex ultrasonography and CT during follow-up visits in patients in whom the pulses could not be palpated, although they were palpable before or in whom the symptoms recurred. For the definitions, >50% stenosis was defined as 100% increase in the

peak systolic velocity compared to adjacent segments, and 70% stenosis was defined as the peak systolic velocity ratio of >3.5. Follow-up visits were scheduled in three-month intervals.

### Statistical analysis

Statistical analysis was performed using the IBM SPSS version 20.0 software (IBM Corp., Armonk, NY, USA). Descriptive data were expressed in mean and standard deviation (SD), median (interquartile range [IQR]) or number and frequency. The Shapiro-Wilk test was used to test for normality. A *p* value of <0.05 was considered statistically significant.

## RESULTS

Baseline demographic and disease characteristics and symptoms of the patients are given in Table 1. The diagnosis of SIAD was made based on the imaging methods applied for other reasons in two (15.4%) of the patients, while four (30.8%) patients had intermittent claudication, two (15.4%) patients had acute ischemia of the lower extremity, two (15.4%) patients had

intermittent abdominal pain, and three (23.1%) patients had lower extremity necrosis as symptoms at the time of admission.

All distal pulses were present in the lower extremity during vascular examination in six (46.2%) patients. Femoral artery pulse was palpable in three (23%) patients, while pulse distension was found to decrease, compared to the contralateral femoral artery. No lower extremity pulses including the femoral artery pulse were palpable in four (30.8%) patients with SIAD. Vascular examination was also evaluated using ABI in each patient. The index was in the range of 0.91 to 1.4 in six (46.2%) patients, while it was <0.9 in three (23%) and 0.4 in four (30.8%) of them. The ABI was detected to be in the range of 0.91 to 1.4 in all patients after treatment.

Computed tomography scans revealed that five (35.7%) of the SIAD cases were confined only to the external iliac artery, while nine (64.3%) of them were observed as co-involvement of the common iliac and external iliac artery. It was detected to be bilateral in one (7.7%) patient. Dissection in this patient was symmetrical and was a total dissection of the common iliac artery and external iliac artery. Four (28.5%) of SIADs were seen in the right iliac artery, while eight (71.5%) of them were located in the left iliac artery. Calcification was detected in the abdominal aorta in seven (53.8%) patients, while it was detected in the iliac artery in 11 (84.6%) of the patients. True lumen compression was between 25 to 50% in five (38.5%) patients, while it was >50%

**Table 1. Baseline and demographic and clinical characteristics of patients (n=13)**

Variable	n	%	Mean±SD
Age (year)			67.9±5.7
Sex			
Male	12	92.3	
Female	1	7.7	
Smoking			
Yes	6	46.2	
Quit	6	46.2	
Never	1	7.7	
Atherosclerotic risk factors			
Hypertension	7	53.8	
Diabetes	6	46.2	
Dyslipidemia	10	76.9	
Pulmonary disease	3	23	
Heart disease	4	30.8	
Asymptomatic	2	15.4	
Symptomatic			
Claudication	4	30.8	
Limb ischemia	2	15.4	
Limb necrosis	3	23	
Abdominal pain	2	15.4	
Ankle-brachial index			
0.91-1.4	6	46.2	
<0.9	3	23	
<0.4	4	30.8	

SD: Standard deviation.

**Table 2. Initial CT findings of patients**

	n
Location of dissection	
Left common iliac artery	6
Right common iliac artery	3
Left external iliac artery	9
Right external iliac artery	5
Internal iliac artery dissection	2
Dissection extending to the common femoral artery	5
Abdominal aorta calcification	7
Iliac artery calcification	11
Compression of true lumen	
25-50%	5
>50%	9
Entry points	13
Reentry points	5

CT: Computed tomography.

in the remaining patients (61.6%). The dissection entry site could be detected in all cases of SIAD with endovascular intervention, but the re-entry site could be detected in only five (38.46%) of them. The dissection was extending to the internal iliac artery in two (15.4%) patients, and they had abdominal pain as the complaint on admission. The dissection was extending to the common femoral artery in five (38.5%) of the dissections starting from the iliac artery. The CT findings of the patients are shown in Table 2.

The dissection was confined to iliac arteries and no hybrid treatment was required in eight (61.6%) patients who underwent endovascular procedure for the treatment of SIAD. Hybrid treatment was performed in five (38.5%) patients, since the dissection extended to the common femoral artery. One (7.7%) of the patients undergoing hybrid treatment had no occlusion at the distal common femoral artery, while the remaining four (30.8%) patients underwent embolectomy due to development of occlusion in the superficial femoral artery following endovascular intervention to the iliac artery. Distal patency was achieved, and the flow was ensured in two (15.4%) of these patients; however, the embolectomy catheter could not be advanced in the other two (15.4%) patients, and these patients underwent a femoropopliteal bypass procedure. Unilateral internal iliac artery and bilateral iliac artery closure by endovascular approach was performed in seven (53.8%) patients and one (7.7%) patient, respectively in all iliac artery dissections extending from the common iliac artery to the external iliac artery and dissections extending to the internal iliac artery.

The primary patency rate was found to be 100%. Intra-stent balloon was performed in four (30.8%) patients with a residual stenosis of >30% after covered stent application. The technical success rate was also 100%. The balloon was inflated with pressures between 6 to 16 atm pressure to provide the necessary clearance and prevent leak in intra-stent balloon angioplasty.

The mean follow-up was  $12.5 \pm 1.12$  (range, 6 to 16) months. The mean length of hospital stay was  $4.9 \pm 2.05$  (range, 3 to 10) days. No mortality occurred in any patient during the hospital stay and one-year follow-up period. Doppler ultrasonography was performed in all patients during the follow-up period. The patients undergoing hybrid treatment were evaluated using CT angiography in the follow-up visits. No complications developed during the follow-up of the patients and no false lumen patency and intra-stent occlusion was observed at the end of the follow-up period. None of the patients experienced any extremity losses.

## DISCUSSION

In the present study, we evaluated whether endovascular and hybrid treatments could be safely and effectively applied in SIAD without restricting and complicating surgical interventions which might be required in the future. As a result of this study, both the technical success and vascular patency rates were 100% during approximately one-year follow-up. Endovascular and hybrid interventions can be effectively and safely applied in SIADs and they enable the application of surgical treatments which may be required in the future.

Spontaneous iliac artery dissection has not been fully defined due to its rarity and presentation with variable clinical and anatomical findings. Although endovascular treatment methods have become the first choice in the iliac artery occlusions thanks to the developing methods in recent years, no consensus has yet been achieved in the treatment of SIAD.<sup>[4-10]</sup> Positive results of medical follow-up of SIAD have been reported;<sup>[11]</sup> however, the general opinion is that interventions should be made to prevent iliac artery rupture, lower extremity ischemia, continuous pain, and possible aneurysmal degeneration.<sup>[12]</sup> The treatment to be applied can be a classical surgical method or endovascular method. Classical surgical methods are associated with increased mortality and morbidity and prolonged hospital stay.<sup>[13]</sup> Nevertheless, classical surgical treatment is the only option in patients who are not suitable for endovascular treatment and in the presence of an arterial rupture. Although the results of endovascular treatment of the rarely seen SIAD have been presented in various publications, the methods that can be applied to facilitate the surgical intervention that may be required in the future after endovascular treatment have not been sufficiently emphasized. A restenosis rate of 30 to 40% has been detected in endovascular interventions performed in peripheral vascular diseases.<sup>[14]</sup> Undoubtedly, surgical intervention to a vessel which was applied a covered or uncovered stent is challenging and has an active role in the mortality and morbidity of the patient.

In our study, SIAD was found to be more common in male patients with advanced age, consistent with previous studies.<sup>[11]</sup> This can be attributed to the intense athletic activity and events of exposed trauma. In addition, the most common complaint of the patients at the time of admission was intermittent claudication, particularly in the hip. Previous studies defined hip claudication due to internal iliac artery diseases.<sup>[15]</sup> However, in this present study, no dissection extending to the internal iliac artery could be detected in the

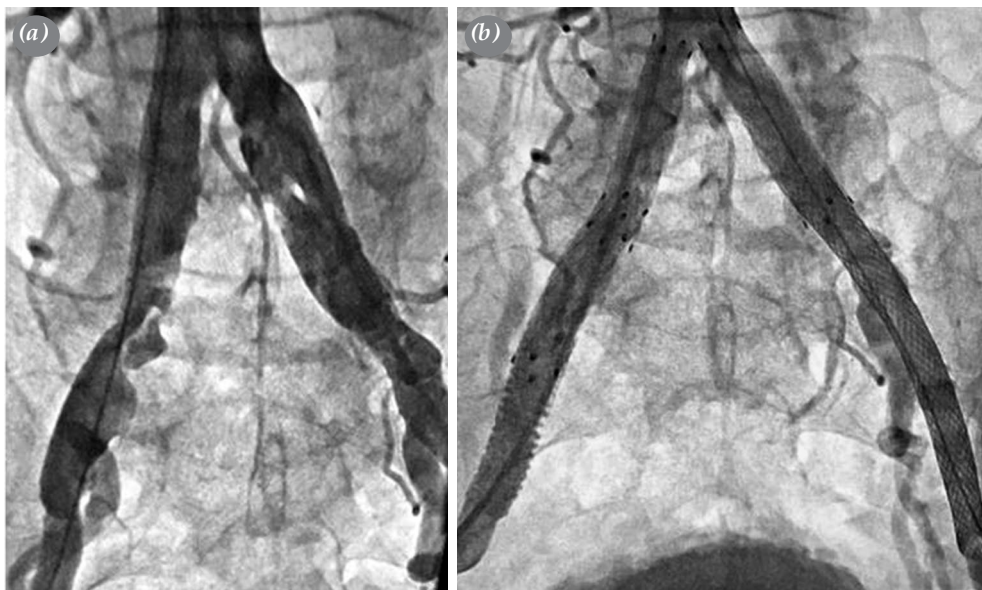
patients with hip claudication, and the involvement was in the form of co-involvement of the common iliac artery and the external iliac artery in these patients. The admission complaint was intermittent abdominal pain in patients with internal iliac artery dissection. Considering the literature data, we applied endovascular intervention to prevent possible iliac artery rupture, lower extremity ischemia, and possible aneurysmal degeneration in asymptomatic patients.<sup>[12]</sup> These findings suggest that intervention is required to prevent future possible aneurysms and catastrophic complications, as vascular wall resistance decreases in asymptomatic SIAD cases diagnosed incidentally.

The most common comorbidity was dyslipidemia, followed by hypertension in our patients. Among the patients, 92.4% were former cigarette smokers and half of them quit smoking. Cigarette smoking, dyslipidemia, hypertension, advanced age, and male sex were frequently observed in patients with SIAD, as in other cardiovascular diseases.<sup>[16,17]</sup> Seven patients had abdominal aortic calcification and 11 patients had calcification in the iliac arteries; therefore, we can speculate that atherosclerosis plays a dominant role in the etiology of iliac artery dissection.

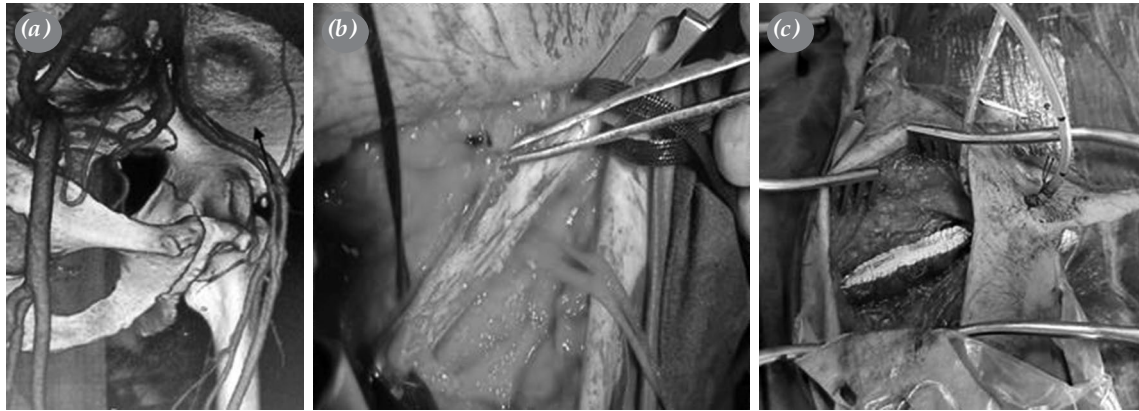
It has been well documented that covered stents have a longer patency in endovascular interventions to the iliac artery, compared to uncovered stents.<sup>[18]</sup> Thus, a covered stent was applied to the proximal of the iliac artery to prevent restenosis in endovascular interventions; however, a self-expandable stent was

overlapped with the covered stent to prevent the false lumen from advancing, and the re-entry site was closed in patients with patency in the false lumen after the application.<sup>[6]</sup> Our goal was to increase stent stability in the entry site and to precisely prevent blood flow to the entry site. Since the pressure in the re-entry site was not as high as in the entry site and the damage in the re-entry site was not as severe as in the entry site, self-expandable stents were applied to the re-entry site. The self-expandable stent was expected to accommodate the diameter of the true lumen which enlarges with the narrowing of the false lumen in the early period. Figure 1 shows the covered stent applied to the proximal iliac artery and the self-expandable stent applied to the distal iliac artery in a patient with bilateral SIAD.

Previous studies have demonstrated no association between SIAD and lower extremity necrosis, since the lower extremity anatomically has an extensive collateral circulation.<sup>[11]</sup> However, in this present study, a circulatory disorder severe enough to cause necrosis or ischemia in the lower extremity was detected in the lower extremity due to SIAD in the patients. The ABI was  $<0.9$  in these patients, SIAD progressed to the common femoral artery in all patients, and a  $>50\%$  compression on the true lumen was found in the evaluation of these patients. After endovascular intervention for SIAD, the dissection in the common femoral artery was sutured through the arteriotomy performed. The dissection line in the common femoral



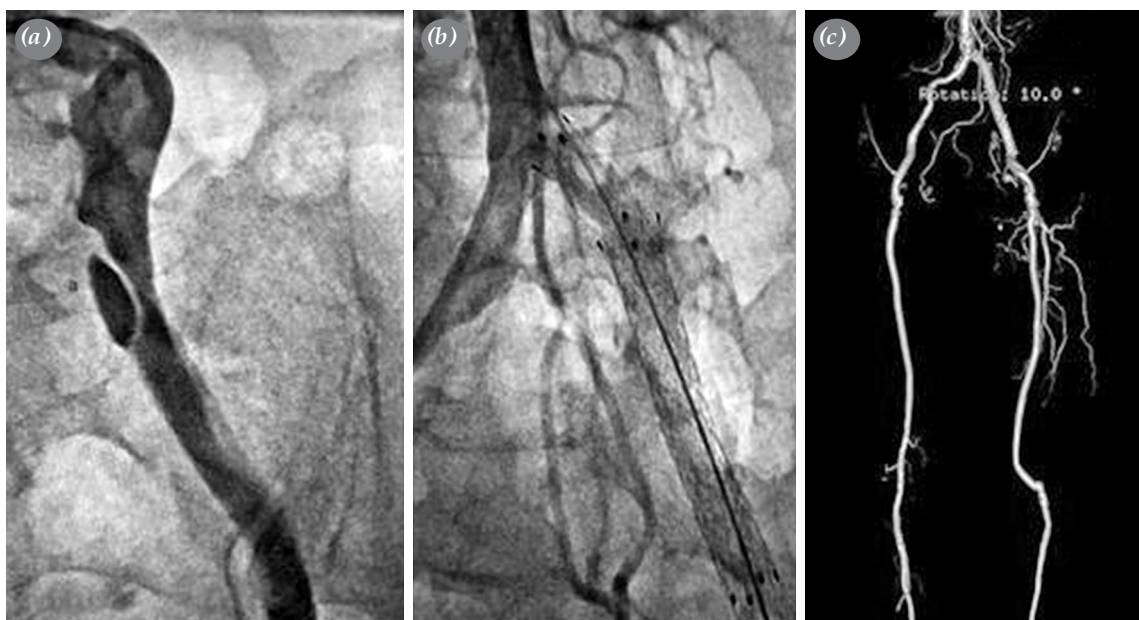**Figure 1.** (a) A conventional angiographic image of a patient with bilateral iliac artery dissection. (b) A conventional angiographic image after endovascular treatment.



**Figure 2.** (a) A computed tomography three-dimensional image of the patient with spontaneous iliac artery dissection, the dissection in the left external iliac artery and dissection extending to the superficial femoral artery. (b) Image of the dissection in the common femoral artery after arteriotomy. (c) Closure of the common femoral artery dissection with patch plasty.

artery was closed with patch plasty, and the artery lumen was expanded in these patients (Figure 2). Embolectomy was performed in four of these patients, since there was no flow at the distal common femoral artery, and femoropopliteal bypass was performed in two patients without flow after embolectomy (Figure 3). We believe that performing ABI and Doppler ultrasonography is sufficient in the follow-up visits of the patients undergoing endovascular intervention alone; however, more advanced imaging

methods should be used in patients undergoing hybrid treatment. Although stent patency is achieved in these patients, extremity salvage depends on the success of hybrid treatment. As a result of our study, we suggest that hybrid treatment reduces mortality and morbidity in cases of dissection extending to the common femoral artery, in cases with  $>50\%$  maximal compression in the true lumen and in patients with a reduced ABI. Eight patients whose internal iliac artery was closed by endovascular intervention had no postoperative



**Figure 3.** (a) Conventional angiographic image of the dissection in the common iliac artery. (b) Conventional image of the common iliac artery after endovascular treatment. (c) Detection of the patient's femoropopliteal bypass patency by three-dimensional computed tomography in the follow-ups after endovascular intervention to the left common iliac artery and left femoropopliteal bypass operation.

complications. We suggest that internal iliac artery closure can be applied in selected cases, since the lower extremities have a highly developed collateral vascular structures. The main goal of all procedures performed in this present study was to protect the stent-free vascular structure for the surgical procedure to be applied in the future in case the patient had intra-stent occlusion in the postoperative period.

The main limitations of the present study included its retrospective nature, small sample size, the lack of the control group, and relatively short follow-up. Further large-scale, long-term, prospective, randomized clinical trials are needed to confirm the effectiveness of endovascular treatment.

In conclusion, successful results up to 100% can be achieved with endovascular treatment for spontaneous iliac artery dissections for one-year follow-up. We believe that the endovascular treatment of spontaneous iliac artery dissections can be performed with minimal peri- and postoperative complications in a way which allows for classical surgery that may be required in the future.

#### **Declaration of conflicting interests**

The authors declared no conflicts of interest with respect to the authorship and/or publication of this article.

#### **Funding**

The authors received no financial support for the research and/or authorship of this article.

#### **REFERENCES**

1. Jia ZZ, Zhao JW, Tian F, Li SQ, Wang K, Wang Y, et al. Initial and middle-term results of treatment for symptomatic spontaneous isolated dissection of superior mesenteric artery. *Eur J Vasc Endovasc Surg* 2013;45:502-8.
2. Zha B, Zhu H, Liu B, Ye Y, Li J. Preservation of Internal Iliac Artery after Endovascular Repair of Common Iliac Artery Dissection Using Modified Fenestrated Stent Graft. *Korean Circ J* 2016;46:412-6.
3. Yoong S, Heyes G, Davison GW, Hannon R, O'Donnell ME. Spontaneous dissection of the external iliac artery secondary to golf club manufacturing. *Vasc Endovascular Surg* 2013;47:73-5.
4. Sun J, Li DL, Wu ZH, He YY, Zhu QQ, Zhang HK. Morphologic findings and management strategy of spontaneous isolated dissection of the celiac artery. *J Vasc Surg* 2016;64:389-94.
5. Lee AD, Mori AM. Iliac artery dissection on noncontrast CT. *Vasc Endovascular Surg* 2011;45:747-8.
6. Yoshida Rde A, Kolvenbach R, Vieira PR, Moura R, Jaldin RG, Yoshida WB. Endovascular treatment of spontaneous isolated common and external iliac artery dissections with preservation of pelvic blood flow. *Ann Vasc Surg* 2015;29:126.e9-14.
7. Temizkan V, Uçak A, Alp İ, Kardeşoğlu E, Selçuk A, Can MF, et al. Our experiences on endovascular and hybrid treatment of peripheral arterial diseases. *Turk Gogus Kalp Damar Cerrahisi Derg* 2018;26:237-45.
8. Mwipatayi BP, Sharma S, Daneshmand A, Thomas SD, Vijayan V, Altaf N, et al. Durability of the balloon-expandable covered versus bare-metal stents in the Covered versus Balloon Expandable Stent Trial (COBEST) for the treatment of aortoiliac occlusive disease. *J Vasc Surg* 2016;64:83-94.e1.
9. Mwipatayi BP, Thomas S, Wong J, Temple SE, Vijayan V, Jackson M, et al. A comparison of covered vs bare expandable stents for the treatment of aortoiliac occlusive disease. *J Vasc Surg* 2011;54:1561-70.
10. Tomita K, Obara H, Sekimoto Y, Matsubara K, Watada S, Fujimura N, et al. Evolution of Computed Tomographic Characteristics of Spontaneous Isolated Superior Mesenteric Artery Dissection During Conservative Management. *Circ J* 2016;80:1452-9.
11. Aboyans V, Ricco JB, Bartelink MEL, Björck M, Brodmann M, Cohnert T, et al. 2017 ESC Guidelines on the Diagnosis and Treatment of Peripheral Arterial Diseases, in collaboration with the European Society for Vascular Surgery (ESVS): Document covering atherosclerotic disease of extracranial carotid and vertebral, mesenteric, renal, upper and lower extremity arteries. Endorsed by: the European Stroke Organization (ESO) The Task Force for the Diagnosis and Treatment of Peripheral Arterial Diseases of the European Society of Cardiology (ESC) and of the European Society for Vascular Surgery (ESVS). *Eur Heart J* 2018;39:763-816.
12. Liang Z, Guo W, Du C, Xie Y. Effectiveness of the conservative therapy for spontaneous isolated iliac artery dissection: Preliminary results. *Vascular* 2017;25:649-56.
13. Kwon SH, Oh JH. Successful interventional treatment of a spontaneous right common iliac artery dissection extending retrogradely into the left external iliac artery. *J Vasc Interv Radiol* 2006;17:717-21.
14. Tang QH, Chen J, Hu, CF, Zhang XL. Comparison between endovascular and open surgery for the treatment of peripheral artery diseases: A meta-analysis. *Ann Vasc Surg* 2019;62:484-95.
15. Krankenberg H, Schlüter M, Steinkamp HJ, Bürgelin K, Scheinert D, Schulte KL, et al. Nitinol stent implantation versus percutaneous transluminal angioplasty in superficial femoral artery lesions up to 10 cm in length: the femoral artery stenting trial (FAST). *Circulation* 2007;116:285-92.
16. Kürşat B. Peri-ferik Arter ve Ven Hastalıkları Ulusal Tedavi Kılavuzu. 1. Baskı. İstanbul: Bayçınar Tıbbi Yayıncılık; 2016.
17. Fiorucci B, Tsilimparis N, Rohlfs F, Wipper S, Debus ES, Kölbel T. Isolated Spontaneous Dissection of the Iliac Arteries: False Lumen Embolization as an Adjunct to Percutaneous Stent Grafting. *Ann Vasc Surg* 2017;42:300.e1-300.e5.
18. Özkan M, Teymen B. Endovascular treatment of patients with bilateral internal iliac artery disease and buttock claudication. *Turk Gogus Kalp Dama* 2018;26:565-70.
19. Bekken JA, Jongsma H, Fiolle B. The use of covered stents in aortoiliac obstructions: a systematic review and meta-analysis. *J Cardiovasc Surg (Torino)* 2018;59:14-25.