

WE'VE GOT YOUR SOLUTION

KILLS TB IN 1 MINUTE

Tristel™ DUO DISINFECTANT

Fast-acting, cost-effective

Tristel DUO is designed to provide fast-acting and cost-effective cleaning and disinfection for instruments and non-critical medical devices including ultrasound probes, holders, cables, keyboards, and ultrasound stations. With a maximum kill time of 2 minutes for bacteria and a minimum time of just 1 minute for tuberculosis and fungi, Tristel DUO really packs a punch. Tested and proven effective against HPV, Tristel DUO bridges the gap where low-level disinfection is insufficient and high-level disinfection is impractical and costly.¹

ALCOHOL FREE • BLEACH FREE

The Power is in the Process

- Patented dispensing system generates the active ingredient – chlorine dioxide (ClO₂).
- ClO₂ destroys pathogens by separating electrons from microorganisms' vital structures resulting in molecular imbalance and microorganism death.
- Simply dispense, apply, and allow to dry. Use with any dry wipe.



Tristel DUO is manufactured and marketed in the United States by Parker Laboratories, Inc. as licensed by Tristel.

1. Meyers C, Milici J, Robison R. The ability of two chlorine dioxide chemistries to inactivate human papillomavirus-contaminated endocavitary ultrasound probes and nasendoscopes. *J Med Virol.* 2020 Aug;92(8):1298-1302. doi: 10.1002/jmv.25666. Epub 2020 Feb 4. PMID: 31919857; PMCID: PMC7497195.




Parker Laboratories, Inc.

The sound choice in patient care.™

973.276.9500

parkerlabs.com

Diagnostic Accuracy of Optic Nerve Sheath Diameter Measured with Ocular Ultrasonography in Acute Attack of Chronic Obstructive Pulmonary Disease

Zeliha Copcuoglu, MD, Oya Akpinar Oruc, MD 

Received June 9, 2022, from the Department of Emergency Medicine, Ministry of Health, Afyonkarahisar State Hospital, Afyonkarahisar, Turkey (Z.C.); and Department of Emergency Medicine, School of Medicine, Afyonkarahisar Health Sciences University, Afyonkarahisar, Turkey (O.A.O.). Manuscript accepted for publication September 7, 2022.

The authors declared no conflict of interest for the present study.

The present study is based on a scientific research thesis.

The study was approved by the Non-Interventional Studies Ethics Committee of the University, on 21.04.2016 with protocol number 80558721/104.

Address correspondence to Oya Akpinar Oruc, MD, Department of Emergency Medicine, School of Medicine, Afyonkarahisar Health Sciences University, Afyonkarahisar, Turkey.

E-mail: droyaoruc@gmail.com

Abbreviations

BMI, body mass index; COPD, chronic obstructive pulmonary disease; ICP, intracranial pressure; mMRC, Modified Medical Research Council Dyspnea Scale; ONSD, optic nerve sheath diameter; ROC, receiver operating characteristic; VAS, Visual Analog Scale

doi:10.1002/jum.16106

Objective—The study aimed to evaluate intracranial pressure changes by measuring ONSD before and after treatment in patients with chronic obstructive pulmonary disease (COPD).

Methods—The study was designed as a prospective analysis, in which 56 COPD in acute exacerbation and 50 volunteers. COPD severity was determined by the Dyspnea Scale of Modified Medical Research Council (mMRC). Measurements were made with ocular ultrasonography and linear probe in both eyes.

Results—Both the right and left ONSDs were higher in the patient compared to the control ($P = .017$) and regressed after the treatment ($P = .021$). In the ROC analysis for the predictability of COPD, right eye ONSDs showed a predictive potential for COPD with %75.7 specificity and %68.1 sensitivity at 0.455 cut-off (AUC: 0.727; $P = .0001$; %95CI: 0.609–0.833). Similar to the right eye, the left ONSD presented %74.4 specificity and %67 sensitivity at 0.505 cut-off value (AUC: 0.718; $P = .0001$; %95CI: 0.608–0.841).

Conclusion—The ONSD measurement that was with the help of ocular ultrasonography can be a useful diagnostic tool for symptomatic COPD presenting with an acute attack.

Key Words—intracranial pressure; COPD; optic nerve sheath diameter; ocular ultrasonography

Chronic obstructive pulmonary disease (COPD) is one of the chronic diseases that cause significant mortality and morbidity worldwide.¹ Despite the decrease in death rates with reliable new generation drugs and treatments, applications to emergency services due to COPD exacerbation are increasing as a result of the increase in smoking prevalence.^{2,3} Increasing rates of it become essential for physicians in the emergency care to have quick decision-making mechanisms against this common and fatal disease.⁴

Patients presenting with COPD exacerbation needs to be evaluated very well in terms of its clinical situation.⁵ In this sense, since the general condition of these patients is poor, dyspneic and tachypneic, arterial blood gas analysis is absolutely necessary to have detailed information about their routine blood, metabolic

and respiratory status.⁶ Arterial puncture done for blood gas analysis is often painful and may cause hematoma, infection, hemorrhage, aneurysm, embolization, or thrombus during its application.⁷ With the passage of blood-borne viruses, it also puts healthcare workers at unnecessary risk. For these reasons, the need for novel or practical non-interventional tests that can give an idea about blood gas values have increased.^{2,8}

The optic nerve sheath, which has a trabeculated arachnoid space through which the cerebrospinal fluid slowly drains, is structurally continuous with the dura-mater.^{9,10} The structural main material of the nervous tissue observed on ultrasound is homogeneous and has low-reflectivity compared to the sheath.¹¹ Intracranial pressure (ICP) can be determined by measuring the optic nerve diameter with ultrasound (ONSD), which is a noninvasive and cost-effective, painless method in emergency room conditions.¹²⁻¹⁴

The present study aimed to detect the ICP seen in COPD with optic nerve diameter changes, and to investigate the usability of optic nerve sheath measurement with ocular ultrasonography as an alternative tool for COPD with acute attack.

Materials and Methods

Ethical Statement

This prospective clinical cross-sectional analysis that was conducted with COPD Patients (n:56), who presented to the Emergency Department of the University Medical Faculty Hospital with acute exacerbation, and the control group (n:50) was approved by the Non-Interventional Studies Ethics Committee of the University, on 21.04.2016 with protocol number 80558721/104. A voluntary consent form was created for the individuals who agreed to participate in the present study and their consent was obtained before including the study. While 24 of the patient group were female and 32 males, 22 of the participants in the control group were females and 28 males.

Participation in the Study

The study group included 56 patients over the age of 40 who were diagnosed with COPD in the past and presented with acute exacerbation to the Emergency

Department of the University Hospital, and 50 healthy-participants who has matched demographics with the patient group such as age, gender and BMI. We enrolled participants among the healthy people who were not diagnosed with COPD or related pulmonary disease in the past. We excluded from the study, if they have one of these criteria: a history of disease (intracranial mass, edema, hematoma, abscess, presence of cyst, hydrocephalus, seizure history), pregnant, suspected intoxication, those who did not agree to participate in the study, and those under 40.

Assessment of COPD

A standard data collection and follow-up form was created for the study and control groups, with the approval of the ethics committee. Spirometry values, clinical and blood gas evaluation were carried out together for the diagnosis of COPD. Demographic features such as age, gender, contact information, height, weight, body mass index (BMI), CV and family history findings, and vital signs at the time of admission were recorded in addition to clinical features such as the reasons for admission, examination findings, how many years have been followed with the diagnosis of COPD, the presence of headache, the severity of headache if present (Visual Analog Scale = VAS), and the characteristics of headache. In the patient group included in the study, the severity of the disease was determined with the help of the Modified Medical Research Council Dyspnea Scale (mMRC).^{15,16} 17.9% of them are in mMRC-1, 23.2% in mMRC-2, 41.1% in mMRC-3 and 17.9% in mMRC-4 group. Arterial blood gases were analyzed at the time of admission. Optic nerve diameter measurement was performed by ultrasonography in all included participants. The Short Form-36 (SF-36) performance questionnaire was applied to the study group as a quality-of-life questionnaire.

Arterial Blood Gas

Arterial blood gases from the patient group were taken from the radial artery after Allen's test, using a heparin-washed insulin syringe in accordance with aseptic rules, and evaluated in approximately 1 ml of blood sample. In the patient group, arterial blood gas analyzes were evaluated with the Radiometer ABL 700 Series blood gas device, and pH, PaO₂ (partial

oxygen pressure), PaCO₂ (partial carbon dioxide pressure), SaO₂ (arterial oxygen saturation), COHb (carboxyhemoglobin), lactate measurements were made.

Evaluation of Optic Nerve

Optic nerve sheath diameter evaluation in the study group was performed by a single emergency medicine assistant who had received relevant ultrasonography training. For the ONSD measurements to be reliable, they were repeated twice and the average was recorded. These measurements were performed in the clinical evaluation area located in the emergency unit. A standard USG machine (Terason brand) with a linear probe was used in the examinations.¹⁷ This option was proper to dedicated ocular settings as Food and Drug Administration (FDA) recommended. The acoustic output in spectral (pulsed) and color Doppler modes did not exceed the FDA's maximum recommended levels for the eye. The measurements were made in the supine position in patients who could tolerate it, and in a semi-sitting position with eyes closed and looking straight ahead in patients who could not tolerate it and had increased respiratory distress. After rubbing water on both eyelids with a clean cotton ball, the linear ultrasound probe was placed in a patient-specific non-sterile glove and performed horizontally over the eyelid. Optic nerve sheath measurement was made from the area between the hyperechoic dural sheaths located on the edge of the hypoechoic subarachnoid area surrounding the optic nerve. Optic nerve sheath diameter over 5 mm was considered significant.¹⁰

Statistical Evaluation

In the study, frequency analysis was given for the distribution of nominal and ordinal data, and mean and standard deviation values were given for the definition of measurement data. Before the difference analysis

of the measurement data, Kolmogorov–Smirnov test was performed to test the homogeneity of the distribution of the data. According to the test results, the independent sample *T*-test was used in the double-group difference analysis of the normally distributed data, and the one-way ANOVA test was used in the analysis of more than two samples difference. Mann Whitney *U*-test was used for the difference analysis of paired groups when the distribution of the data did not fit the normal distribution. Pearson's rho correlation was used in the correlation analysis. A receiver operating characteristic (ROC) curve was used to assess the diagnostic efficiency of the ONSD measurement for the diagnosis of COPD. All analyzes were performed with a 95% confidence interval and SPSS v17.0 for Windows package program.

Results

Demographic Data

The mean age was 69.9 + 9.8 in the patient and 69.6 + 10.2 in the control. While the mean body mass index (BMI) of the patient group was 27.1 + 6.3 kg/m², the mean BMI of the control was 27.8 + 4.9 kg/m². The COPD diagnosis history of our patients was as follows: 0 to 5 years for 35.7% (n:20), 6 to 10 years for 30.4% (n:17), 11 to 15 years for 16.1% (n:9), and more than 15 years for 17.9% (n:10). No significant difference was found in demographic data (*P* > .05).

Optic Nerve Sheath Diameter

As shared in Tables 1 and 2, when the patient group came to the emergency room, the optic nerve sheath diameter (ONSD) of the right and left eyes were measured and compared with the measurements of the control group. The mean admission right eye ONSD was 5.1 ± 0.7 mm in the patient group, while the right eye ONSD average in the control group was 4.7 ± 0.7 mm. The presentation of mean left eye ONSD was 5.2 ± 0.7 mm in the patient, and 4.7 ± 0.6 mm in the control. Both the right and left ONSD values were significantly higher in the patient compared to the control (*P* < .05). The right and left eye ONSDs were compared before and after COPD attack treatment in the patient group. While the mean right eye ONSD of the patient group was

Table 1. Optic Nerve Sheath Diameter Values in the COPD and Control Groups

ONSD (Groups)	Patients (n:56)	Control (n:56)	<i>P</i>
The right eye, mm	5.1 ± 0.7	4.7 ± 0.7	.029
The left eye, mm	5.2 ± 0.7	4.7 ± 0.6	.004

Independent *T*-test was used to analyze the groups. ONSD, optic nerve sheath diameter.

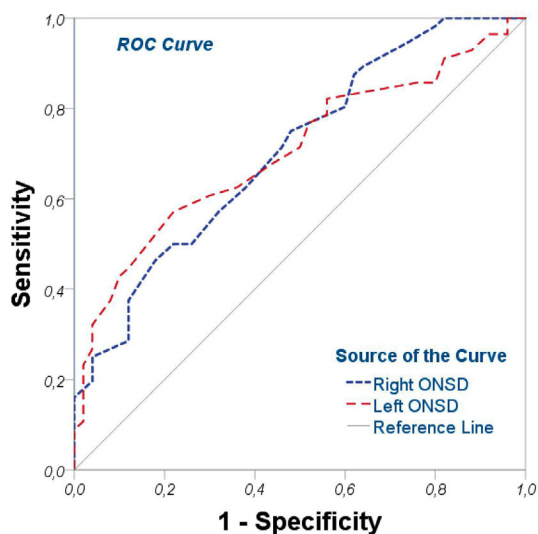
5.1 ± 0.7 mm before treatment, it was 4.8 ± 0.7 mm after treatment. While the mean left eye ONSD was 5.2 ± 0.7 mm before treatment, it was 4.8 ± 0.7 mm after treatment. Both right eye ONSD and left eye ONSD values were found to be significantly higher in the patient group before COPD attack treatment than after treatment ($P < .05$).

Table 2. The Comparison of Before–After the COPD Treatment

ONSD (Treatment)	Before (n:56)	After (n:56)	P
The right eye, mm	5.1 ± 0.7	4.8 ± 0.7	.0001
The left eye, mm	5.2 ± 0.7	4.8 ± 0.7	.0001

Independent T-test was used to analyze the groups. ONSD, Optic nerve sheath diameter.

Figure 1. The ROC analysis of optic nerve sheath diameter changes with ultrasonography in chronic obstructive pulmonary disease



In the ROC analysis we did for the predictability of COPD, we found a diagnostic potential of ONSDs, as we see in Figure 1. Right eye ONSDs showed a predictive potential for COPD with %75.7 specificity and %68.1 sensitivity at 0.455 cut-off value (AUC: 0.727; $P = .0001$; %95 confidence interval: 0.609–0.833). Similar to the right eye, the left ONSD presented %74.4 specificity and %67 sensitivity at 0.505 cut-off value (AUC: 0.718; $P = .0001$; %95 confidence interval: 0.608–0.841).

mMRC analysis

The patients’ presentation right and left eye ONSDs were compared between the mMRC groups. When examined among mMRC groups; It was observed that ONSD increased as the severity of COPD increased, but the difference was not significant ($P > .05$). In order to better understand the effects of COPD severity on ONSD, the patient group was grouped as mild (mMRC 0 and 1) and severe (mMRC 2, 3 and 4) and the results are shown in Table 3. When ONSD was analyzed according to the mMRC mild and the mMRC severe groups; the left ONSD value was significant between the groups ($P < .05$), while the right eye ONSD values did not show a significant difference according to the alterations ($P > .05$).

The patient group was divided into two groups according to the mMRC scale, 0–1 as the mild and 2–4 as the severe group. These two groups were evaluated according to the parameters of the SF-36 performance questionnaire, and a difference was found between the two groups only in terms of physical function ($P < .05$). There is no difference in the patient group in terms of other parameters.

Table 3. Difference Between ONSD Values of COPD

ONSD (Groups)	mMRC ₁ (n = 10)	mMRC ₂ (n = 13)	mMRC ₃ (n = 23)	mMRC ₄ (n = 10)	P
The right eye, mm	4.9 ± 0.7	5.2 ± 0.9	5.0 ± 0.7	5.3 ± 0.9	.676
The left eye, mm	5.0 ± 0.9	5.3 ± 0.9	5.2 ± 0.7	5.3 ± 0.8	.708
ONSD (Severity)	mMRC Mild (n = 10)		mMRC Severe (n = 46)		P
The right eye, mm	5.1 ± 0.9		5.1 ± 0.7		.852
The left eye, mm	4.8 ± 0.9		5.3 ± 0.7		.032

ONSD, optic nerve sheath diameter; mMRC, Modified Medical Research Council Independent T-test was used to analyze the groups.

Blood Gas Analysis

In the patient group, when the entrance and exit left ONSD were examined according to the output PaO₂, PaCO₂ and saturation groups. A significant alteration was observed in the group with oxygen 60–79, the group with carbon dioxide <35 and 36–44, and the group with %90–100 saturation ($P < .05$). When the correlation between the admission blood gas values of the patient group and the admission ONSD was examined, a negative correlation was only found between the O₂ value and the admission right ONSD ($r = -0.332$; $P < .05$). Apart from this, no relationship was found between ONSD and other blood gas parameters ($P > .05$).

Discussion

The ONSD values, which we look at in the right and left eyes, will be a very useful tool for physicians in understanding the practice and can be integrated into the routine as a diagnostic device. The use of ONSD measurements with the help of ocular USG can be a guide in the follow-up of the response to the treatment applied to symptomatic COPD presenting with an acute attack.

Today, largely invasive methods are used to detect intracranial pressure changes. Intracranial pressure is a condition related to the hypoxia and hypercarbia.¹² A prospective self-controlled non-randomized trial study by Duyan and Saridas, investigated the correlation between differences in ONSD and changes in PaCO₂ and pH values before and after treatment in COPD.¹⁸ They reported that the ONSD changed significantly and in a highly correlated manner to acute changes in PaCO₂ levels. Measuring the diameter of the optic nerve sheath can give information about the increase in intracranial pressure. In the present study, intracranial pressure changes were investigated in COPD presenting with acute exacerbation by measuring optic nerve sheath diameter (ONSD) with the help of ultrasonography. ONSD increased in patients presenting with COPD acute exacerbation. The finding that the optic disc diameters decreased after treatment in COPD patients suggested that hypoxia and hypercarbia were effective in optic disc diameter.

The optic nerve is a continuation of the central nervous system and continues as the dura mater layer of the brain in the head.¹⁹ There is a subarachnoid space-like structure associated with the intracranial subarachnoid space in the perineural space between the optic nerve and its sheath. In cases of increased intracranial pressure, CSF-fluid is displaced towards the optic nerve sheath.²⁰ These changes can be evaluated with ocular USG. It has become a method that can be used in emergency services in recent years, with its easy applicability, possibility of repeated measurements, and no radiation. Although there is still debate about the cutoff value that best shows the increase in intracranial pressure, the normal value for ONSD is accepted as 4.5–5 mm. In the study conducted by Goel et al., in which patients with head trauma were discussed the sensitivity of optic nerve USG in detecting the presence of intracranial pathologies.²¹ In our study, the average ONSD measured by USG was 5.2 ± 0.7 in our patient and 4.7 ± 0.7 in our control group, and the mean of the measurements in our patient group is above 5 mm.

In the meta-analysis conducted by Dubourg et al., the results of ONSD measurements made with the help of optical USG for the evaluation of intracranial pressure and measurements made with invasive methods were compared. As a result of this research, ONSD measurements are 90% sensitive and 85% specific in detecting increased intracranial pressure. In a study, optical USG applications could be a guide in determining the approaches to be applied to patients.²² In the ROC that we performed for the predictability of COPD; we found a diagnostic potential of ONSD. Right eye ONSDs showed a predictive potential for COPD with %75.7 specificity and %68.1 sensitivity. Similar to the right eye, the left ONSD presented %74.4 specificity and %67 sensitivity for COPD. The data obtained in our study suggest that PaO₂ may have an important role in pressure changes. A negative relationship was found between hypoxia and ONSD, and in the light of the data obtained, hypoxia may play a role in the changes intracranial pressure and these changes could be evaluated with the help of USG.

In the present study, there was no significant difference in the analysis of mMRC values showing the degree of dyspnea in the analyzes performed from 1 to 4, but we found a significant difference in the left

eye in the classification made as severe and mild. Although we can explain this situation as the left eye is affected by COPD more than the right eye, we consider that more large cross-sectional studies should be investigated in order to use precise statements. The strength of the present research is that assessment of optic nerve sheath diameter changes with ultrasonography in chronic obstructive pulmonary was tested by us for the first time with this analysis to the best acknowledge of us. As major limitation, the limited number of patients evaluated and the fact that intracranial pressure was not evaluated with a different method other than ultrasonography. Although it was tried to determine whether the cases had comorbidities that would affect the ONSD measurement, the possibility of the existence of undiagnosed or incomplete data. ICP were indirectly analyzed that no gold standard to actually say that ICP was elevated. Although the physician who made the evaluation in the study worked according to scientific principles, the evaluation with a single physician unfortunately prevented a blind review of images.

Conclusion

The increase in intracranial pressure in patients during the acute exacerbation of COPD was demonstrated with the help of ultrasonography, and it was determined that these findings regressed after the treatment. Ocular ultrasonography can be used in the follow-up of intracranial pressure changes in COPD that there was a negative relationship between partial oxygen pressure and ONSD. Its measurements can be a guide in blood gas monitoring. The use of ultrasonography, which does not contain radiation and is an easily applicable diagnostic tool, in the diagnosis and follow-up of patients with suspected intracranial pressure increase can provide important information to clinicians working in emergency departments.

REFERENCES

- Duffy SP, Criner GJ. Chronic obstructive pulmonary disease: evaluation and management. *Med Clin North Am* 2019; 103:453–461. <https://doi.org/10.1016/j.mcna.2018.12.005>.
- Ferrera MC, Labaki WW, Han MK. Advances in chronic obstructive pulmonary disease. *Annu Rev Med* 2021; 72:119–134. <https://doi.org/10.1146/annurev-med-080919-112707>.
- Nguyen PL, Uddin MM, Mir T, et al. Trends in incidence, and mortality of acute exacerbation of chronic obstructive pulmonary disease in the United States Emergency Department (2010–2018). *COPD: J Chronic Obstr Pulm Dis* 2021; 18:567–575. <https://doi.org/10.1080/15412555.2021.1979500>.
- Chen L, Chen L, Zheng H, Wu S, Wang S. Emergency admission parameters for predicting in-hospital mortality in patients with acute exacerbations of chronic obstructive pulmonary disease with hypercapnic respiratory failure. *BMC Pulm Med* 2021; 21:258. <https://doi.org/10.1186/s12890-021-01624-1>.
- Riley CM, Sciruba FC. Diagnosis and outpatient management of chronic obstructive pulmonary disease: a review. *JAMA* 2019; 321:786–797. <https://doi.org/10.1001/jama.2019.0131>.
- Ak A, Ogun CO, Bayir A, Kayis SA, Koylu R. Prediction of arterial blood gas values from venous blood gas values in patients with acute exacerbation of chronic obstructive pulmonary disease. *Tohoku J Exp Med* 2006; 210:285–290. <https://doi.org/10.1620/tjem.210.285>.
- Oddershede L, Petersen SS, Kristensen AK, Pedersen JF, Rees SE, Ehlers L. The cost-effectiveness of venous-converted acid-base and blood gas status in pulmonary medical departments. *Clinicoecon Outcomes Res* 2011; 3:1–7. <https://doi.org/10.2147/CEOR.S14489>.
- Ritchie AI, Wedzicha JA. Definition, causes, pathogenesis, and consequences of chronic obstructive pulmonary disease exacerbations. *Clin Chest Med* 2020; 41:421–438. <https://doi.org/10.1016/j.jccm.2020.06.007>.
- Besir A, Akdogan A, Guvercin AR. Optic nerve sheath diameter with intracranial pressure monitoring: a non-invasive method to follow children with craniosynostosis. *Cir Cir* 2021; 89:13–16. Diámetro de la vaina del nervio óptico con monitorización de la presión intracraneal: un método no invasivo para el seguimiento de niños con craneosinostosis. <https://doi.org/10.24875/ciru.21000113>.
- Hylkema C. Optic nerve sheath diameter ultrasound and the diagnosis of increased intracranial pressure. *Crit Care Nurs Clin North Am* 2016; 28:95–99. <https://doi.org/10.1016/j.cnc.2015.10.005>.
- Agrawal D, Raghavendran K, Zhao L, Rajajee V. A prospective study of optic nerve ultrasound for the detection of elevated intracranial pressure in severe traumatic brain injury. *Crit Care Med* 2020; 48:e1278–e1285. <https://doi.org/10.1097/CCM.0000000000004689>.
- Donovan J, Oanh PKN, Dobbs N, et al. Optic nerve sheath ultrasound for the detection and monitoring of raised intracranial pressure in tuberculous meningitis. *Clin Infect Dis* 2021; 73:e3536–e3544. <https://doi.org/10.1093/cid/ciaa1823>.
- Lochner P, Czosnyka M, Naldi A, et al. Optic nerve sheath diameter: present and future perspectives for neurologists and critical

- care physicians. *Neurol Sci* 2019; 40:2447–2457. <https://doi.org/10.1007/s10072-019-04015-x>.
14. Rayner M, Holt T, Daspal S, Mondal P, Langford L, Hansen G. Optic nerve sheath diameter in preterm infants: suggested values. *Neonatology* 2021; 118:297–300. <https://doi.org/10.1159/000513721>.
 15. Natori H, Kawayama T, Suetomo M, et al. Evaluation of the Modified Medical Research Council Dyspnea scale for predicting hospitalization and exacerbation in Japanese Patients with chronic obstructive pulmonary disease. *Intern Med* 2016; 55:15–24. <https://doi.org/10.2169/internalmedicine.55.4490>.
 16. Yasui H, Inui N, Karayama M, et al. Correlation of the modified Medical Research Council dyspnea scale with airway structure assessed by three-dimensional CT in patients with chronic obstructive pulmonary disease. *Respir Med* 2019; 146:76–80. <https://doi.org/10.1016/j.rmed.2018.11.020>.
 17. Major R, Girling S, Boyle A. Ultrasound measurement of optic nerve sheath diameter in patients with a clinical suspicion of raised intracranial pressure. *Emerg Med J* 2010; 28:679–681. <https://doi.org/10.1136/emj.2009.087353>.
 18. Duyan M, Saridas A. Relation between partial arterial carbon dioxide pressure and pH value and optic nerve sheath diameter: a prospective self-controlled non-randomized trial study. *J Ultrasound* 2022. <https://doi.org/10.1007/s40477-022-00677-0>.
 19. Malayeri AA, Bavarian S, Mehdizadeh M. Sonographic evaluation of optic nerve diameter in children with raised intracranial pressure. *J Ultrasound Med* 2005; 24:143–147. <https://doi.org/10.7863/jum.2005.24.2.143>.
 20. Soldatos T, Chatzimichail K, Papathanasiou M, Gouliamos A. Optic nerve sonography: a new window for the non-invasive evaluation of intracranial pressure in brain injury. *Emerg Med J* 2009; 26:630–634. <https://doi.org/10.1136/emj.2008.058453>.
 21. Goel RS, Goyal NK, Dharap SB, Kumar M, Gore MA. Utility of optic nerve ultrasonography in head injury. *Injury* 2008; 39:519–524. <https://doi.org/10.1016/j.injury.2007.09.029>.
 22. Dubourg J, Javouhey E, Geeraerts T, Messerer M, Kassai B. Ultrasonography of optic nerve sheath diameter for detection of raised intracranial pressure: a systematic review and meta-analysis. *Intensive Care Med* 2011; 37:1059–1068. <https://doi.org/10.1007/s00134-011-2224-2>.