



Access this article online

Quick Response Code:



Website:

www.turkjemergmed.org

DOI:

10.4103/2452-2473.276385

A rare condition in the third trimester of pregnancy: Ovarian torsion

Halil Yildirim, Serife Ozdinc*

Department of Emergency Medicine, School of Medicine, Afyonkarahisar University of Health Sciences, Afyonkarahisar, Turkey

Abstract:

Ovarian torsion (OT) during pregnancy is a rare condition that can cause maternal and fetal morbidity. Although the etiology of the disease is not fully understood, predisposing factors include increased ovarian size, free mobility, and long pedicle. The incidence of the disease increases after ovarian stimulation for the treatment of fertility. Diagnostic imaging modalities include ultrasonography and magnetic resonance imaging (MRI). A 28-year-old woman with a 33-week pregnancy presented to our emergency department with acute, severe left groin pain. According to the patient's declaration, she had her first pregnancy, which was acquired by intrauterine insemination in another center. Her vital signs were unremarkable except for tachycardia. Physical examination revealed guarding (*défense musculaire*) and rebound tenderness on the left lower quadrant of the abdomen. Laboratory and imaging studies were performed for the preliminary diagnosis of acute abdomen. She was diagnosed with OT and admitted to the department of obstetrics and gynecology. OT should be included in the differential diagnosis of patients with suspected acute abdomen in advanced stages of pregnancy. In addition, MRI should be used as an alternative diagnostic modality in patients with normal sonographic findings.

Keywords:

Abdominal pain, magnetic resonance imaging, ovary, pregnancy, torsion

Introduction

Abdominal and pelvic pains are among the most common causes of admission to the emergency department (ED). There are many causes of abdominal and pelvic pain in women; but among these, ovarian torsion (OT) can be associated with high morbidity if left undiagnosed.^[1] OT is defined as the complete or partial rotation of the adnexa around its vascular axis or pedicle. Although the exact etiology is obscure, predisposing factors include increased ovarian size, free mobility, and long pedicle.^[2] The incidence increases after ovarian stimulation during *in vitro* fertilization (IVF).^[3] The frequency of

OT in patients presenting to the ED with acute abdominal pain is 3%.^[4] Although its incidence during pregnancy is uncertain, it has been reported to be 1–5/10,000 in some studies.^[1,2,5] In particular, it is more common in the first trimester of pregnancy.^[5]

OT may be more difficult to diagnose due to physiological and anatomical changes during pregnancy and may be misdiagnosed with other conditions, such as rupture of corpus luteum cyst, hyperstimulation of ovaries, urinary obstruction, and acute appendicitis.^[6-8] Ancillary diagnostic methods may include ultrasonography (USG), Doppler USG, and magnetic resonance imaging (MRI).^[7]

In this case report, in the light of literature, we aimed to discuss a 33-week pregnant patient who presented to our ED with acute, severe left groin pain and was diagnosed

This is an open access journal, and articles are distributed under the terms of the Creative Commons Attribution-NonCommercial-ShareAlike 4.0 License, which allows others to remix, tweak, and build upon the work non-commercially, as long as appropriate credit is given and the new creations are licensed under the identical terms.

How to cite this article: Yildirim H, Ozdinc S. A rare condition in the third trimester of pregnancy: Ovarian torsion. *Turk J Emerg Med* 2020;20:42-5.

For reprints contact: reprints@medknow.com

Received: 25-10-2019

Accepted: 02-11-2019

Published: 28-01-2020

ORCID:

0000-0003-1574-0207

0000-0003-3948-8501

Address for correspondence:

Dr. Serife Ozdinc,
Afyonkarahisar University
of Health Sciences,
Faculty of Medicine,
Department of Emergency
Medicine, Ali Çetinkaya
Campus, Dörtöyl District,
2078 Street., No. 3/4,
Afyonkarahisar, Turkey.
E-mail: drseri03@hotmail.com

with an OT that could not be demonstrated by USG but proved by MRI.

Case Report

A 28-year-old woman with a 33-week pregnancy presented to our ED with acute left groin pain of increasing severity, which started at noon on the same day and spread to the left side of her abdomen. According to the patient's declaration, she had her first pregnancy acquired by intrauterine insemination (IUI) in another center. A complete review of her medical history revealed no record of a disease, drug use, or surgery.

The patient's vital signs were unremarkable except for tachycardia. Physical examination revealed *défense musculaire* and rebound tenderness on the left lower quadrant of the abdomen. On admission, she was given intravenous hydration and symptomatic treatment for the preliminary diagnosis of acute abdomen.

In laboratory studies, complete blood count revealed leukocytosis (13.100/ μ L), neutrophilia (12.150/ μ L), and anemia (hemoglobin: 11.3 g/dL), whereas urine analysis showed no abnormal findings. A complete abdominal USG examination performed by a radiologist showed the presence of fetal heartbeat and bilateral multicystic (each with an average size of 4 cm \times 5 cm) ovaries with dimensions of 9 cm \times 10 cm. However, ovarian blood flow was not clearly demonstrated by Doppler USG. Due to the absence of a diagnostic result by USG and a progression of symptoms despite treatment, noncontrast MRI was scheduled after obtaining informed consent. MRI showed cysts that may be secondary to IUI, reaching 6.5 cm in the right ovary and 6 cm in the left ovary [Figure 1]. In addition, MRI showed signs suggestive of OT in the left ovary, including peripherally arranged cysts, microcysts

harboring the peripheral hypointense hemosiderin ring, marked stromal edema, free fluid in the inferior part of the ovary, and suspected whirlpool sign in the vascular pedicle [Figures 2 and 3]. Finally, the patient was diagnosed with OT and transferred to the department of obstetrics and gynecology. The patient underwent an emergency operation and was discharged after 3 days of hospitalization.

Discussion

OT is a rare cause of gynecological emergencies.^[5] Rotation of the adnexa on its pedicle primarily causes venous flow stasis, which ultimately results in ischemia and necrosis as a result of interruption of arterial flow.^[4] Although the exact incidence during pregnancy is unknown, it has been reported to be 1–5/10,000 in some studies.^[2,5] In particular, it is more common in the first trimester of pregnancy.^[5]

The rotation of the ovary/ adnexa on its axis or pedicle including vascular structures give rise to obstruction of arterial, venous, and lymphatic flows, resulting in massive congestion, infarction, and hemorrhagic necrosis in the parenchyma of the ovary.^[4] Although the cause of adnexal torsion is not completely known, an increase in adnexal mobility due to a long tube and a long utero-ovarian ligament have been reported as predisposing factors of adnexal torsion.^[4,8] Assisted reproductive techniques, the presence of an ovarian cyst and mass, induction of ovulation, and previous adnexal torsion are considered as potential risk factors.^[9] Although the incidence of OT increases after ovarian stimulation for IVF, as in our case, there are insufficient data on the prevalence of these patients.^[3]

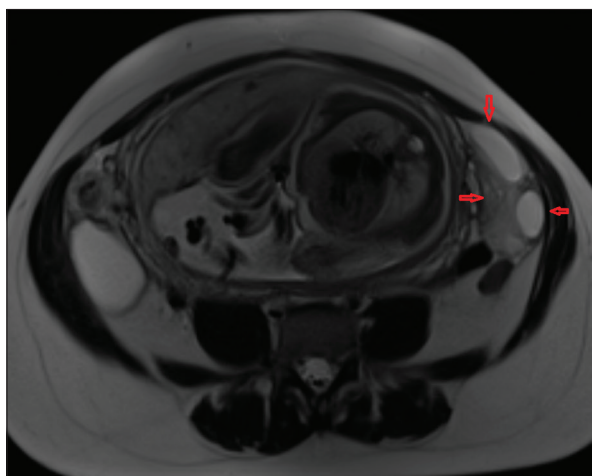


Figure 1: Axial T2-weighted magnetic resonance imaging showing peripherally arranged cysts and findings of stromal edema

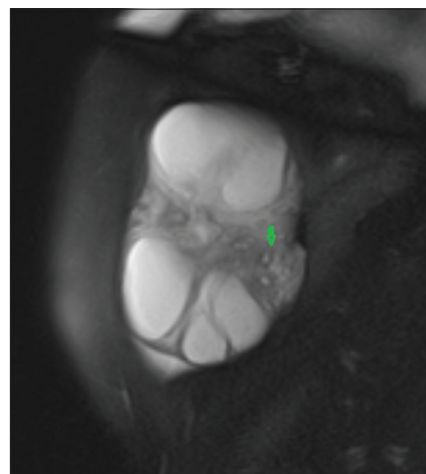


Figure 2: Fat-suppressed sagittal T2-weighted magnetic resonance imaging showing increased ovarian size, peripherally arranged cysts, microcysts harboring the peripheral hypointense hemosiderin ring, marked stromal edema, and free fluid in the inferior part of the ovary

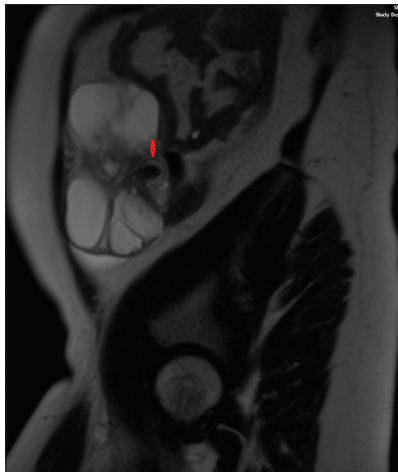


Figure 3: Sagittal T2-weighted magnetic resonance imaging showing suspected whirlpool sign in the vascular pedicle

The frequency of ovarian and adnexal torsions on the right side is higher than on the left side due to the higher mobility of cecum or distal ileum, higher length of the mesothelium of the adnexa and higher frequency of ovarian and adnexal torsions on the right side than on the left side, and restriction of adnexal movements by the sigmoid colon on the left side.^[6,9] In our case, we detected torsion of the left ovary.

Patients with OT often present with acute onset severe pelvic pain (90%), which may be accompanied by signs and symptoms such as nausea and vomiting (47%–70%), normal body temperature (2%–20%), and leukocytosis or adnexal mass (86%–95%).^[9] Accordingly, our patient was admitted to our ED with severe groin pain.

Diagnosis of OT becomes difficult due to the absence of specific signs and symptoms and the wide variety of other abdominal pathologies.^[5,10] Given the physiological and anatomical changes associated with pregnancy, OT becomes more difficult to diagnose and can often be misdiagnosed with other conditions such as rupture of the corpus luteum cyst, ovarian hyperstimulation, diverticulitis, pelvic inflammatory disease, urinary obstruction, and appendicitis.^[4,6] Clinical examination is generally hampered by anatomical displacement of the abdominal organs by the enlarged uterus.

USG is considered to be the best first-line imaging modality for evaluating the etiology of abdominal pain during pregnancy. However, it is difficult to visualize the ovaries in the second and third trimesters due to displacements in the expanding uterus and pelvis.^[6] Peripherally arranged follicles, rotated vascular pedicle, free fluid around ovary, enlarged ovary (>5 cm), and “whirlpool” sign have been considered as sonographic findings of OT.^[4] Our patient had no other findings other than the enlarged ovary. Doppler USG may miss

the diagnosis depending on the degree and timing of torsion. In the early stages of torsion, only venous and lymphatic flows may be affected, whereas arterial flow may remain unaffected. Therefore, the only evidence of blood flow does not rule out OT. Bacanakgil *et al.* showed that 60% of patients diagnosed with OT had normal Doppler USG findings.^[4]

MRI is an alternative imaging method for the diagnosis of OT. MRI is well tolerated during pregnancy and may be useful for the evaluation of sonographically ambiguous adnexal lesions. MRI can visualize the structure of an inverted pedicle or an adnexal mass in more detail than ultrasound.^[7,11] The MRI findings of OT include whirlpool sign, peripherally arranged cysts, stromal edema, ovarian hemorrhage, rotated ovarian pedicle, thickening of the tubal wall (more than 10 mm), symmetrical and asymmetric increase in wall thickness of ovarian cyst, and ipsilateral deviation of the uterus.^[9] Our patient also had some of these findings. Béranger-Gibert *et al.* reported that MRI has an accuracy rate of more than 80% for the diagnosis of adnexal torsion in patients presenting with acute pelvic pain.^[11] In our case, we also observed that MRI has a higher diagnostic value than USG for the diagnosis of adnexal torsion.

Torsion should be treated conservatively or radically in pregnant women as well as in nonpregnant women. Conservative treatment modalities may include detorsion of the ovary. However, radical treatment modalities may include adnexal oophorectomy and salpingo-oophorectomy, if there is no improvement in ischemic symptoms despite detorsion.

Conclusion

OT, which may cause maternal and fetal morbidity, is an important condition that should be kept in mind in the differential diagnosis of pregnant patients admitted to the ED with acute abdominal pain. OT is a rare and more difficult diagnosis in the later stages of pregnancy. Proper diagnosis and timely intervention are also important to prevent miscarriages and potential abdominopelvic inflammatory reactions, especially in young women when maintenance of fertility is desired. Although USG is a commonly used diagnostic tool, it may not be able to provide accurate evaluation of adnexal structures. MRI should be used as an alternative imaging modality for patients with clinically suspected adnexal torsion that cannot be diagnosed by sonographic methods.

Declaration of patient consent

The authors certify that they have obtained all appropriate patient consent forms. In the form the patient(s) has/have given his/her/their consent for his/her/their

images and other clinical information to be reported in the journal. The patients understand that their names and initials will not be published and due efforts will be made to conceal their identity, but anonymity cannot be guaranteed.

Author contribution statement

Literature search, manuscript preparation and editing were done by HY. Manuscript review was done by SO. Concepts, design, definition of intellectual content, final approval were done by HY and SO.

Funding

None.

Conflicts of interest

The authors declare no conflict of interest.

References

1. Robertson JJ, Long B, Koyfman A. Myths in the evaluation and management of ovarian torsion. *J Emerg Med* 2017;52:449-56.
2. Nasiri A, Rahimi S, Tomlinson E. Ovarian torsion in pregnancy: A case report. *Gynecol Obstet Case Rep* 2017;3:1-2.
3. Romanski PA, Melamed A, Elias KM, Stanic AK, Anchan RM. Association between peak estradiol levels and ovarian torsion among symptomatic patients receiving gonadotropin treatment. *J Assist Reprod Genet* 2017;34:627-31.
4. Bacanakgil BH, Kaban I, Deveci M, Hasanova M. Ovarian torsion: 10 years' experience of a tertiary medical center. *İstanbul Med J* 2018;19:258-62.
5. Mathew M, Ghaithi HA, Shukaili SA, Shivrudraiah G. Torsion of normal adnexa in the third trimester of pregnancy mimicking acute appendicitis. *EMJ Reprod Health* 2017;3:54-6.
6. Li C, Wang S, Tao X, Hu Y, Li X, Xiao X. Torsion of normal-sized ovary during late pregnancy: A case report and review of the literature. *J Obstet Gynaecol Res* 2018;44:2110-4.
7. Singh T, Prabhakar N, Singla V, Bagga R, Khandelwal N. Spectrum of magnetic resonance imaging findings in ovarian torsion. *Pol J Radiol* 2018;83:e588-99.
8. Vaswani B, Laddad M. Torsion of ovarian cyst during pregnancy – A case report. *J Evol Med Dent Sci* 2016;5:6897-8.
9. Ozer CA, Uzun ND, Uzun F, Terzi H. A case report in the third trimester pregnancy: Ovarian torsion, a rare cause of acute abdomen. *Ann Case Rep* 2018;207:1-3.
10. Morton MJ, Masterson M, Hoffmann B. Case report: Ovarian torsion in pregnancy – Diagnosis and management. *J Emerg Med* 2013;45:348-51.
11. Béranger-Gibert S, Sakly H, Ballester M, Rockall A, Bornes M, Bazot M, *et al.* Diagnostic value of MR imaging in the diagnosis of adnexal torsion. *Radiology* 2016;279:461-70.