

ITPA Related Developmental Encephalopathy: Key Role of Neuroimaging

Dilek Çavuşoğlu, Melike Ataseven Kulali¹, Nihal Olgaç Dünder², Cigdem Ozer Gokaslan³, Kurşad Aydın⁴

Departments of Pediatric Neurology, ¹Pediatric Genetics and ³Radiology, Faculty of Medicine, Afyonkarahisar Health Sciences University, Afyon, ²Department of Pediatric Neurology, Faculty of Medicine, İzmir Katip Celebi University, İzmir, ⁴Department of Pediatric Neurology, Istanbul Medipol University, Istanbul, Turkey

CLINICAL DESCRIPTION

A 4-month-old girl presented with poor head control. She was born at term without complications. Parents were nonconsanguineous but from the same village. Her neurological examination revealed normal deep tendon reflexes with flexor plantar responses. She had microcephaly (head circumference 36 cm, -3.5 SD) and also dysmorphic features including a high arched palate, long philtrum, anteverted auricles. Metabolic studies including ammonia, serum amino acids, urine organic acids, acylcarnitine profile, lactate, pyruvate levels, and thyroid function studies were normal. Magnetic resonance imaging (MRI) of the brain showed delayed myelination (hyperintensities in the posterior limb of internal capsule) in the T2-weighted image and restricted diffusion in the posterior limb of the internal capsule, optic radiation, cerebral peduncles, substantia nigra, the pyramidal tracts in the midbrain, and cerebellar white matter [Figure 1]. After one month of follow-up, the patient exhibited intractable tonic seizures. Interictal electroencephalogram showed focal spike and slow waves in the left occipital region. She was treated with phenobarbital, levetiracetam, and topiramate. Whole-exome sequencing (WES) analysis revealed a homozygous pathogenic splice-site variant c. 124 + 1G > A located in intron 2 of ITPA gene (PVS1, PM2, PP3, PP5). This variant had been reported previously (rs376142053).

DISCUSSION

Inosine triphosphate pyrophosphohydrolase (ITPA) related developmental encephalopathy is a rare early infantile developmental encephalopathy. Clinical manifestations mostly consist of hypotonia, development delay, progressive microcephaly, and epilepsy. Some patients have cataracts and cardiomyopathy, too. Dysmorphic features are also described as large and low set ears, micrognathia, hypertelorism, low nasal bridge, long philtrum, epicanthal folds, short nose. This case presents hypotonia, development delay, microcephaly, epilepsy, dysmorphic features, and a peculiar brain MRI pattern which especially lead to the diagnosis of ITPA related developmental encephalopathy. The term 'ITPA related developmental encephalopathy' was used because of the development delay exhibited before epileptic seizures and epileptiform abnormalities in the patient. Therefore, it may be suggested developmental delay is independent of epilepsy. Characteristic brain MRI findings distinctly contribute to the diagnosis.^[1-3] Firstly, Kevelam *et al.*^[1] reported seven individuals from four

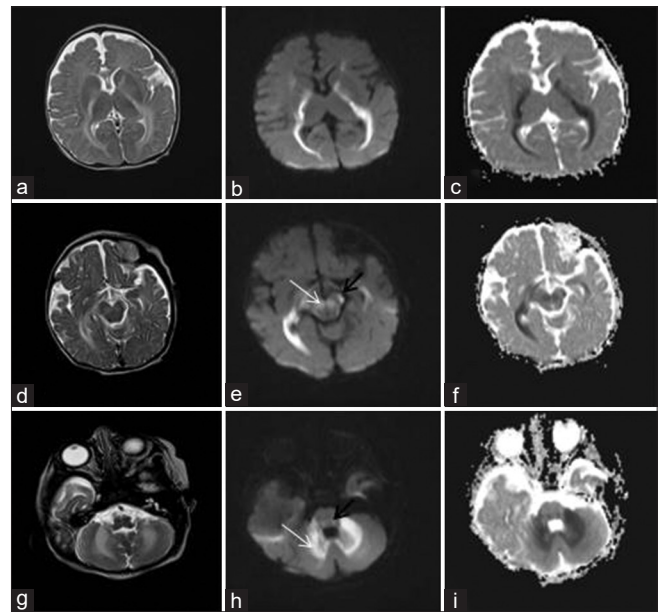


Figure 1: T2-weighted MRI images revealed hyperintensity in the posterior limb of internal capsule, optic radiation (a), cerebral peduncles, substantia nigra (d), and cerebellar white matter (g). Diffusion-weighted and ADC MRI images showed restricted diffusion in the posterior limb of internal capsule, optic radiation (b and c), cerebral peduncles (e and f; black arrow), substantia nigra (e; white arrow), the pyramidal tracts in the midbrain (h and i; black arrow), and cerebellar white matter (h and i; white arrow)

families with this disorder. MRIs of all patients pointed to delayed myelination, thin corpus callosum, and T2 weighted hyperintensities in the posterior limb of the internal capsule. Several patients also displayed involvement of the pyramidal tracts in the midbrain, middle and inferior cerebellar peduncles, and cerebellar white matter. Additionally, diffusion-weighted imaging showed diffusion restriction in the posterior limb of the internal capsule in all of them except one patient and some patients also in the optic radiation and midbrain. All of the patients exhibited cerebral atrophy in the follow-up. Then, Kaur *et al.*^[2] reported one patient with delayed myelination, thin corpus callosum, T2 weighted hyperintensities in the posterior limb of the internal capsule, and mild cerebral atrophy. Sakamoto *et al.*^[3] described two patients with T2 hyperintensity of the pyramidal tracts in the internal capsule, and midbrain, delayed myelination of the posterior limb of the internal capsule, and optic radiation, cerebral atrophy, and thin corpus callosum. Recently, Muthusamy *et al.*^[4] reported one patient

with the same mutation as our patient. The MRI of the patient indicated the lack of myelination in cerebellar white matter and posterior limb of the internal capsule and also restricted diffusion involving optic radiations, cerebral peduncles, red nuclei, globus pallidus, and corticospinal tract. In particular, Krabbe disease can be considered the differential diagnosis for the involvement of the corticospinal tract. However, it does not typically exhibit restricted diffusion of the tracts.

We highlight characteristic neuroimaging features including T2 hyperintensity and restricted diffusion of the posterior limb of the internal capsule, optic radiation cerebral peduncles, substantia nigra, the pyramidal tracts in the midbrain, and cerebellar white matter with a lack of myelination are key to the diagnosis of ITPA related developmental encephalopathy.

Declaration of patient consent

The authors certify that they have obtained all appropriate patient consent forms. In the form the patient(s) has/have given his/her/their consent for his/her/their images and other clinical information to be reported in the journal. The patients understand that their names and initials will not be published and due efforts will be made to conceal their identity, but anonymity cannot be guaranteed.

Financial support and sponsorship

Nil.

Conflicts of interest

There are no conflicts of interest.

REFERENCES

1. Kevelam SH, Bierau J, Salvarinova R, Agrawal S, Honzik T, Visser D, *et al.* Recessive ITPA mutations cause an early infantile encephalopathy. *Ann Neurol* 2015;78:649–58.
2. Kaur P, Neethukrishna K, Kumble A, Girisha KM, Shukla A. Identification of a novel homozygous variant confirms ITPA as a developmental and epileptic encephalopathy gene. *Am J Med Genet A* 2019;179:857–61.
3. Sakamoto M, Kouhei D, Haniffa M, Silva S, Troncoso M, Santander P, *et al.* A novel ITPA variant causes epileptic encephalopathy with multiple-organ dysfunction. *J Hum Genet* 2020;65:751–7.
4. Muthusamy K, Boyer S, Patterson M, Bierau J, Wortmann S, Morava E. Teaching neuroimages: Neuroimaging findings in inosine triphosphate pyrophosphohydrolase deficiency. *Neurology* 2021;97:e109–10.

Address for correspondence: Dr. Dilek Çavuşoğlu,

Department of Pediatric Neurology, Faculty of Medicine, Afyonkarahisar Health Sciences University, Ali Çetinkaya Kampüsü Dörtüol Mah, 2078 Sok, No. 3/4 Afyonkarahisar, Afyon - 03100, Turkey.
E-mail: dilekcavusoglu83@gmail.com

Submitted: 20-Nov-2021 **Accepted:** 18-Dec-2021 **Published:** 18-Feb-2022

This is an open access journal, and articles are distributed under the terms of the Creative Commons Attribution-NonCommercial-ShareAlike 4.0 License, which allows others to remix, tweak, and build upon the work non-commercially, as long as appropriate credit is given and the new creations are licensed under the identical terms.

For reprints contact: WKHLRPMedknow_reprints@wolterskluwer.com

DOI: 10.4103/aian.aian_999_21