

The Effect of Nd:YAG Laser Posterior Capsulotomy on Macular Pigment Optical Density in Cases with Posterior Capsule Opacification

Arka Kapsül Kesafeti Olan Olgularda Nd:YAG Lazer Posterior Kapsülötominin Maküla Pigmenti Optik Yoğunluğuna Etkisi

^{id} Bünyamin KUTLUKSAMAN^a, ^{id} Mustafa DOĞAN^b

^aKahramanmaraş Necip Fazıl City Hospital, Clinic of Ophthalmology, Kahramanmaraş, TURKEY

^bAfyonkarahisar University of Health Sciences Faculty of Medicine, Department of Ophthalmology, Afyonkarahisar, TURKEY

This study was presented as a poster at 53rd National Congress of the Turkish Ophthalmology Association, 06-10 November 2019, Antalya, Turkey.

ABSTRACT Objective: To investigate the effect of ND:YAG laser capsulotomy on macular pigment optical density(MPOD) in patients with posterior capsule opacification(PCO). **Material and Methods:** This prospective and single-arm clinical trial included 38 participants with pseudophakic eyes. MPOD, choroidal(CT) and central macular thicknesses(CMT), as well as anterior chamber parameters, were measured before ND:YAG laser and the measurements were repeated after one week, one month and two months. The changes in the parameters and correlations were evaluated statistically. **Results:** There were significant decreases in the MPODs of the fovea and pericentral during the study ($p<0.01$ for both). The mean ICA (iridocorneal angle), ACD (anterior chamber depth) and CMT significantly increased during the study period ($p<0.01$). The mean CTs of the nasal and subfoveal regions also increased significantly ($p<0.01$). There were significant negative correlations between the changes in the mean total applied laser energy and MPODs ($r>0.6$, $p<0.01$), and there were significant and same direction relations between the changes in the mean total laser energy, and ICA, ACD, as well as CMT($r>0.6$, $p<0.01$). **Conclusion:** Posterior laser capsulotomy resulted in decreases in MPODs, while there were increases in the mean ICA, ACD, CT and CMT. Laser capsulotomy can affect the posterior capsule integrity and macular pigment, therefore, it can cause more vulnerable situations in the retina against high-energy blue lights.

Keywords: Anterior chamber parameters; central macular thickness; macular pigment optical density; neodymium-doped: yttrium aluminium garnet laser; posterior capsule opacification

ÖZET Amaç: Arka kapsül kesafeti (AKK) tanılı hastalarda Nd:YAG lazer kapsülötominin maküla pigmenti optik yoğunluğu (MPOY) üzerine etkisinin araştırılması amaçlanmıştır. **Gereç ve Yöntemler:** Bu prospektif vaka kontrollü çalışmada AKK tanısı alan ve posterior lazer kapsülötomi planlanan 38 hasta çalışmaya dahil edildi. Lazer kapsülötomi uygulaması öncesi bütün katılımcıların MPOY, koroid kalınlığı (KK), iridokorneal açısı (İKA), ön kamara derinliği (ÖKD), santral maküla kalınlığı (SMK) ile birlikte uygulanan lazer kapsülötomi parametreleri kaydedildi. Aynı ölçümler lazer kapsülötomi sonrası 1. hafta, 1. ay ve 2. ayda tekrar edildi ve veriler kaydedildi. Elde edilen verilerin süreç içerisindeki değişimleri ve birbirleri ile korelasyonları istatistiksel olarak değerlendirildi. **Bulgular:** Çalışma süresince fovea ve perisentral MPOY ortalama değerlerinde anlamlı azalma mevcuttu ($p<0,01$, her iki değer için). Çalışma süresince ortalama İKA, ÖKD ve SMK anlamlı olarak arttı ($p<0,01$). Nazal ve subfoveal bölge ortalama KK'de anlamlı olarak arttı ($p<0,01$). Ayrıca uygulanan toplam lazer enerjisi ile MPOY değişimi arasında anlamlı negatif korelasyon mevcut iken ($r>0,6$, $p<0,01$), uygulanan ortalama toplam lazer enerjisi ile İKA, ÖKD ve CMT değişimleri arasında anlamlı ve aynı yönde ilişki mevcuttu ($r>0,6$, $p<0,01$). **Sonuç:** Posterior lazer kapsülötomi MPOY'da azalamaya neden olurken, İKA, ÖKD, KK ve SMK değerlerinde artışlara neden olmuştur. Lazer kapsülötomi işlemi arka kapsül bütünlüğünü ve maküla pigmentini etkileyen bir işlem olarak yüksek enerjili mavi ışığa karşı retinada daha korumasız ve daha hassas bir duruma neden olabilir.

Anahtar Kelimeler: Ön segment parametreleri; santral maküla kalınlığı; maküla pigmenti optik yoğunluğu; neodymium-doped:yttrium aluminium garnet laser; arka kapsül kesafeti

Posterior capsule opacification is a frequent long-term post-operative complication following extracapsular cataract extraction and phacoemulsifica-

tion with posterior chamber intraocular lens implantation.¹ The literature has reported that the incidence of posterior capsule opacification after cataract sur-

Correspondence: Bünyamin KUTLUKSAMAN
Kahramanmaraş Necip Fazıl City Hospital, Clinic of Ophthalmology, Kahramanmaraş, TURKEY/TÜRKİYE
E-mail: bkutluksaman@gmail.com



Peer review under responsibility of Türkiye Klinikleri Journal of Ophthalmology.

Received: 29 Oct 2019

Received in revised form: 03 Feb 2020

Accepted: 04 Feb 2020

Available online: 10 Feb 2020

2146-9008 / Copyright © 2020 by Türkiye Klinikleri. This is an open access article under the CC BY-NC-ND license (<http://creativecommons.org/licenses/by-nc-nd/4.0/>).

gergy and intraocular lens implantation varies between 7 and 43%.^{2,3}

Neodymium-doped: Yttrium Aluminium Garnet (Nd: YAG) laser posterior capsulotomy is a standard method for the management of posterior capsule opacification. On the other hand, although it is a safe, non-invasive and time-trusted procedure, it is associated with several complications, such as intraocular pressure rise, iritis, hyphema, uveitis, intraocular lens pits, intraocular lens movement, corneal haze and disruption of the anterior hyaloid surface. In addition to short-term adverse effects, such as intraocular pressure spikes or iritis, Nd: YAG laser capsulotomy may also be associated with long-term and severe complications, such as glaucoma, posterior vitreous detachment, cystoid macular edema or retinal detachment.^{4,5}

Slomovic and Parrish have reported that an increase in intraocular pressure after Nd: YAG laser posterior capsulotomy is related to the blockage of meshwork due to capsular debris and vitreous particles moving to the anterior chamber.⁶ The floating of particles and debris to the anterior chamber may cause the changes of anterior chamber parameters, such as anterior chamber depth and iridocorneal angle. Besides the motion of debris and particles, some researchers have also suggested that inflammatory mediators, which release from the anterior chamber or ciliary body, can easily diffuse to the macula.⁷ Retinal changes such as cystoid macular edema, even changes in choroid, are likely to occur due to affected macula. The study about the comparison of Nd: YAG laser posterior capsulotomy size and choroidal thickness, has claimed that Nd: YAG capsulotomy causes the thickening of choroid.⁸

One of the structures situated in the retina is macular pigment. The macular pigment has a critical role in absorbing high-energy visible (HEV) blue lights that have the potential of damaging to the retina. An ophthalmologist can foresee that macular pigment protecting the retina from oxidative damage may be affected in events occurring in the retina. Furthermore, many previous studies have shown substantial reductions in macular pigment optical density concerning age-related macular degeneration. However, not only in age-related macular degeneration but also after Nd: YAG laser capsulotomy, the sub-

ject that macular pigment optical density (MPOD) may be affected due to adverse effects associated with inflammatory mediators or thermal damage of Nd: YAG laser posterior capsulotomy is worth investigating. There are limited clinical studies about this issue in the literature. Besides anterior chamber parameters and choroidal thickness, the effects of Nd: YAG laser capsulotomy on MPOD should also be topics to be discussed owing to its crucial role in the retina.

In this study, we aimed to investigate the effects of Nd: YAG laser posterior capsulotomy on MPOD, anterior chamber parameters, choroidal and retinal thicknesses, and to detect correlations between the parameters.

MATERIAL AND METHODS

This clinical trial was conducted following the principles of the Declaration of Helsinki (2008). The local authorized clinical trials ethics committee approved the protocol and consent forms (Afyon Kocatepe University Clinical Trials Ethics Committee, 2011-KAEK-2 2017/172). www.ClinicalTrials.gov (identification, NCT03321253) registered the protocol. Between 2015 and 2016, this study included 38 enrolled pseudophakic participants ranging from 45 to 65 years who had previously undergone cataract surgery without prior Nd: YAG laser posterior capsulotomy and panretinal photocoagulation (PRP).

Detailed ophthalmological examinations of participants were performed before Nd: YAG laser posterior capsulotomy. Intraocular pressure (IOP) was measured using AT900 Haag-Streit Diagnostics applanation tonometer (Haag-Streit AG, Koeniz, Switzerland). Biomicroscopic and fundus examinations (using SuperField NC non-contact slit-lamp lens; Volk Optical Inc, Mentor, OH, USA) were performed using Topcon SL-D701 slit-lamp biomicroscopy (Topcon Co, Tokyo, Japan). Gonioscopic findings were viewed using a four-mirror gonio lens (Volk G-4 Four-mirror glass gonio lens; Volk Optical Inc, Mentor, OH, USA). Anterior chamber parameters (ACD) were measured using an anterior segment module of Heidelberg - The Spectralis optical coherence tomography (OCT) (Heidelberg Engineering Inc, Heidelberg, Germany). The iridocorneal

angle (ICA) termed the mean of anterior chamber angles in nasal and temporal regions in the anterior segment OCT (Figure 1A). Slit-lamp and fundus examinations, as well as the measurements of central macular thickness, choroidal thicknesses and MPODs, were performed after maximal pupil dilatation. Anterior segment parameters and correlations were also examined to determine the mechanism where MPOD is affected in our study. For example; the changes in the lens and its position caused by laser applied to posterior capsule, and the correlation between mechanical effect created in the vitreous and the changes in MPOD, besides the correlation between the applied laser energy and changes in MPOD, may give us a preliminary idea about the mechanisms and therefore we designed the study to include anterior segment parameters.

Proposed procedures, including risks, benefits and alternatives, were discussed with all subjects, and all participants signed an informed consent form. Patients who had only mild to moderate posterior capsule opacification were enrolled in this study to reduce obstacles to measurements. Central macular thickness and choroidal thicknesses were measured using Heidelberg - The Spectralis OCT2 Module OCT (Heidelberg Engineering Inc, Heidelberg, Germany). Central macular thickness was determined and analyzed automatically by OCT software. The 3 mm central retinal thickness area was described as central macular thickness in our study. The mean

macular thickness of five regions in 3 mm central retinal area centered at the fovea based on the Early Treatment Diabetic Retinopathy Study (ETDRS) map termed the mean central macular thickness (Figure 1B). Enhanced depth imaging-OCT mode of the same device was used to measure choroidal thicknesses. Choroidal thicknesses were recorded as subfoveal, nasal, and temporal choroidal thicknesses and they were measured under the fovea, at 3 mm nasal and temporal to the fovea, respectively (Figure 1C).

MPOD measurements were subsequently performed using MonPack System luminance differential thresholds test (Color perimetry technique) (Metrovision Inc, Perenchies, France). The color perimetry technique has a three-stage mechanism. In the first stage, the transmitted and received blue light absorbed by the macular pigment, and the non-absorbable red light in the peripheral region are measured for minimizing the effect of the intraocular media on the measurement and then the comparative values are calculated (Figure 2A). After the determination of the effect of the intraocular media on blue light, the comparative values of red and blue lights' reflections are measured and calculated for the fovea and pericentral regions where both the intraocular media and macular pigment affect the absorption of blue light (Figure 2A). Then, similar to the automatic perimetry, deviation values are evaluated comparing the mean values of age-matched population data,

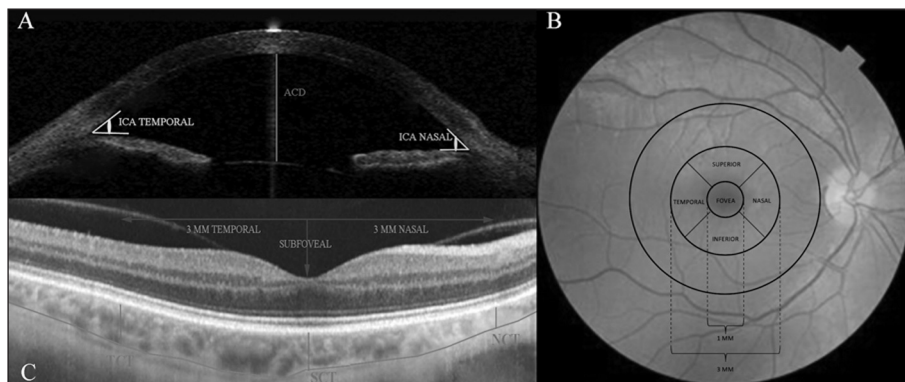


FIGURE 1: A. Evaluation of iridocorneal angle (ICA) in the anterior segment optical coherence tomography with the temporal and nasal anterior chamber angles. The distance between the corneal endothelium and the anterior surface of the intraocular lens was termed as anterior chamber depth (ACD). B. According to the Early Treatment Diabetic Retinopathy Study (ETDRS) map, the mean thickness of the foveal centered 1 mm diameter circular area and its surrounding four pericentral regions were referred to as central macular thickness (CMT). C. Demonstration of the measurements of subfoveal (SCT), nasal (NCT), and temporal (TCT) choroidal thicknesses in EDI-OCT.

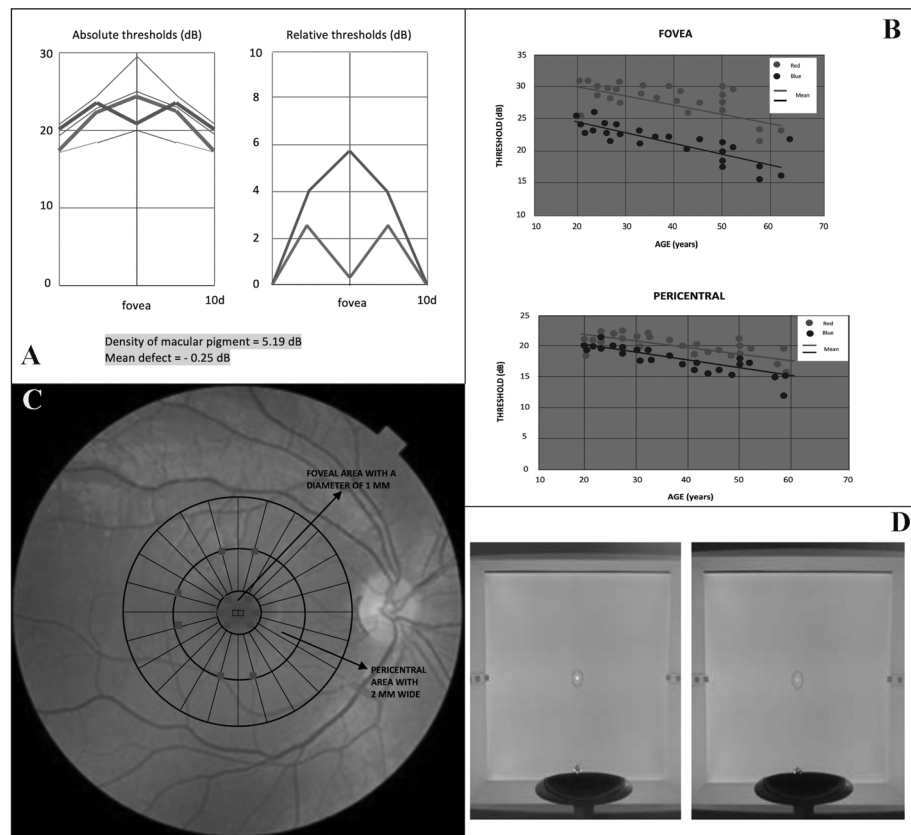


FIGURE 2: The features of color perimetry technique. A. Computation of macular pigment optical density by device software comparing the reflections of absorbed blue light and non-absorbed red light in the retina. DB (Decibel), a comparison unit, was converted to log unit concerning statistical evaluation. B. Evaluation of the mean deviations of thresholds measured in color perimetry method based on the mean values of the age-matched population. C. Locations of 8 points at the fovea and 6 points in the pericentral area based on the Early Treatment Diabetic Retinopathy (ETDRS) map in color perimetry method. D. Reflection of blue and red lights into the retina from the device in color perimetry method.

which consists of approximately 8000 people in our clinic (Figure 2B).

The MPODs were measured for the fovea and pericentral regions based on the ETDRS retinal map regions automatically detected by the device software. The foveal centered 1 mm diameter circular area was referred to as the foveal region, and the foveal centered area within 1 mm and 3 mm circular area was referred to as the pericentral macular area. In the color perimetry method, MPOD is measured, referencing 8 points at the fovea and 6 points in the pericentral macular area (Figure 2C). The device automatically locates the measuring point at the center, providing fixation at different points on the fixation spotlight during the measurement (Figure 2D).

After measurements, a refractive surgeon carried out Nd:YAG laser posterior capsulotomy to patients

using Laserex Tango Nd:YAG laser capsulotomy (Ellex Medical Pty Ltd, Adelaide, SA, Australia). Proparacaine hydrochloride 0.5% eye drop was applied to the cornea before the procedure for topical anesthesia and to use contact lens. Ocular Abraham Iridectomy YAG contact lens (Ocular Inc, Bellevue, WA, USA) was used during the procedure for stabilization of eye, accurate focusing and the laser beam optics. The minimal amount of energy, which is necessary to obtain breakdown and rupture the capsule as possible, was aimed and applied during the procedure. Applied energy that had range from 1 to 2 mJ/pulse was sufficient to open all capsules in this study. The laser was intentionally focused posterior to the capsule to avoid intraocular marks. Eyes that had free-floating fragments, visually significant pits and cracks after capsulotomy were excluded from the study. Applied total energy, the

total number of shots and total duration were recorded for each eye.

After Nd:YAG laser capsulotomy, all subjects were followed up for four hours concerning that they had the potential for increased intraocular pressure and severe acute anterior chamber inflammation. Intraocular pressures were remeasured at one and 4-hour. Subjects' eyes, which had intraocular pressure of 27 mmHg or more and aqueous flares of 2+ or more, were not included in this study. Treatments of Brinzolamide 1% ophthalmic suspension (Azopt; Alcon Co, Fort Worth, TX, USA) twice a day and nepafenac 0.1% ophthalmic solution (Nevanac; Alcon Co, Fort Worth, TX, USA) 3 times a day were initiated to all subjects and used for a week.

All examinations and measurements were repeated and recorded in the first week, first and the second month. All patients told that they continued their regular diet and no participants used supplements containing carotenoids during the study period.

Inclusion criteria:

Best-corrected visual acuity (BCVA) logarithm of minimum angle of resolution (logMAR) <0.3

Duration at least two years after cataract surgery

Between the ages of 45 and 65 years (45≤age≤65)

Exclusion criteria:

Corneal scarring, diffuse capsule opacification or intravitreal hemorrhage that prevents the appearance of the fundus

Occluded angle by gonioscopy (grade 0, narrow-angle, grade I, grade II)

Presence of macular or peripheral retinal pathologies or choroidopathy

High risk for retinal detachment

Presence of macular edema in the macular area

Detection of macular fluid or edema in OCT

Active intraocular inflammation

Previous PRP, Nd:YAG laser posterior capsulotomy, laser iridotomy or selective laser trabeculoplasty interventions

Previous iridectomy, glaucoma or vitreoretinal surgery

Glass intraocular lens

Spherical refractive error $\geq \pm 6.00$ D or cylinder refractive error $\geq \pm 3.00$ D

Inadequate stability of the eye

Systemic diseases that may affect the choroidal blood flow such as cardiological diseases

Current use of carotenoid supplementation

Changing eating habits

Gastrointestinal diseases that can cause disturbance of dietary absorption

STATISTICAL ANALYSIS

Data obtained from cases were encoded and transferred to SPSS 20.0 software (SPSS Inc) for statistical evaluation. The Shapiro-Wilk Test tested normal distributions of variables to assess the changes in recurrent measurements. Repeated measures analysis of variance (ANOVA) performed the variance analysis of normal distribution variables. When the values did not match the normal distribution, changes in the process were evaluated using the Friedman test. The Paired-Samples T-test was used for situations that fit the normal distribution in binary comparisons of the dependent group to assess the changes during the process. The binary comparisons of the dependent group, which was not a normal distribution, were interpreted using the Wilcoxon test, as a non-parametric test. The correlations between variables were analyzed using Pearson test when both variables showed normal distribution according to tests of normality. In the correlation analysis, if even one of the groups did not show a normal distribution, the relationship between the groups was evaluated using Spearman's test. The level of significance in the trial was accepted to be 0.05 of the p-value ($p=0.05$). It was considered that the level of r was 0.6 or more as a strong relationship in the correlation analysis ($r \geq |\pm 0.6|$).

RESULTS

All patients with 38 pseudophakic eyes completed their controls and follow-ups. Analysis of the results

has not shown side effects or conditions that cause the exclusion of a participant from the evaluation. The mean age of the participants was 55.37 ± 4.45 years (Shapiro-Wilk test of normality, $p=0.27$). In this study, the sex ratio between males and females was 1:1 (50%-50%). The eye side ratio between right and left was also 1:1 (50%-50%). The mean duration after cataract surgery was 5.32 ± 2.23 years (Test of normality, $p=0.42$).

The mean MPODs at baseline were 0.55 ± 0.07 logMAR in the fovea and 0.33 ± 0.05 logMAR in the pericentral region (Tests of normality; $p=0.66$ and $p=0.73$, respectively). The mean MPODs at 2-month were 0.5 ± 0.09 logMAR in the fovea and 0.29 ± 0.06 logMAR in the pericentral region (Tests of normality; $p=0.62$ and $p=0.87$, respectively). Repeated measures ANOVA has shown that the mean MPOD in the fovea and the pericentral regions decreased during the study period (Table 1). The mean iridocorneal angle at baseline and 2-month were $36.59 \pm 1.22^\circ$ and $42.04 \pm 4.18^\circ$, respectively (Tests of normality; $p=0.67$ for baseline and $p=0.54$ for 2-month). The significant increase was ascertained in the mean iridocorneal angle for two months in this study (Table 1) (Repeated measures analysis of variance, $p<0.001$). The study group demonstrated a baseline anterior chamber depth of 3.7 ± 0.06 mm ($p=0.9$), which increased to 3.75 ± 0.07 mm ($p=0.73$) at 2-month. During the first month after laser capsulotomy, the mean ante-

rior chamber depth increased significantly (Pairwise comparison from baseline to 1-month in repeated measures analysis of variance, $p<0.001$) and there was less significant change in the mean anterior chamber depth for the next four weeks (Pairwise comparison from 1-month to 2-month in repeated measures analysis of variance, $p=0.05$) (Table 1). Similarly, statistical analysis showed a significant increase in the mean central macular thickness in the first month, but the increase did not significantly continue in the following month (Table 1). The baseline mean central macular thickness was 235.79 ± 13.48 μ m (Test of normality; $p=0.07$) and the mean value was 235.79 ± 13.48 μ m ($p=0.38$) at 2-month. Significant increases in the mean nasal choroidal thickness have been seen; however, we have not observed significant changes in the mean subfoveal and temporal choroidal thicknesses in the study (Table 1).

In this study, the baseline mean BCVA was 0.35 [range: 0.22 – 0.5] logMAR and the mean BCVA increased in the first month after laser capsulotomy (Friedman test, $p<0.001$), but there was no change in the subsequent follow-up (Graphic 1) (The mean BCVA at 2-month was 0.073 [0 – 0.3] logMAR). The mean baseline IOP was 15.81 ± 0.52 mmHg (Test of normality, $p=0.55$), and the mean IOP at 2-month was 15.81 ± 0.42 mmHg (Test of normality, $p=0.21$). Repeated measures ANOVA has shown that intraocular pressure increased significantly in the first week

TABLE 1: The mean values of the parameters during the study (n=38).

	Baseline	1-Week	1-Month	2-Month	P-Value*
MPOD Fovea, log unit	0.55 ± 0.07	0.52 ± 0.08	0.51 ± 0.09	0.5 ± 0.09	<0.001
MPOD Pericentral, log unit	0.33 ± 0.05	0.31 ± 0.05	0.3 ± 0.06	0.29 ± 0.06 **	<0.001
Iridocorneal angle, °	36.59 ± 1.22	39.92 ± 2.1	41.62 ± 3.39	42.04 ± 4.18 †	<0.001
Anterior chamber depth, mm	3.7 ± 0.06	3.73 ± 0.06	3.74 ± 0.06	3.75 ± 0.07 §	<0.001
Central macular thickness, μ m	235.79 ± 13.48	243.08 ± 14.32	244.76 ± 14.82	245.5 ± 15.24 ††	<0.001
Subfoveal choroid thickness, μ m	276.46 ± 19.46	276.54 ± 19.45	276.86 ± 19.42	276.76 ± 19.36	0.08
Nasal choroid thickness, μ m	271.16 ± 19.64	271.33 ± 19.74	271.75 ± 19.71	271.74 ± 19.62 ‡	<0.001
Temporal choroid thickness, μ m	275.04 ± 20.59	275.02 ± 20.67	275.23 ± 20.64	275.03 ± 20.56	1.0

Choroid. = Choroidal, MPOD = Macular pigment optical density.

* Change from baseline (Repeated measures analysis of variance).

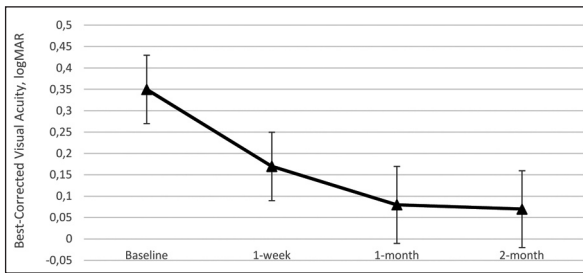
** Change from previous control (Pairwise comparisons in repeated measures analysis of variance), $p = 0.02$.

† Change from previous control (Pairwise comparisons in repeated measures analysis of variance), $p = 0.19$.

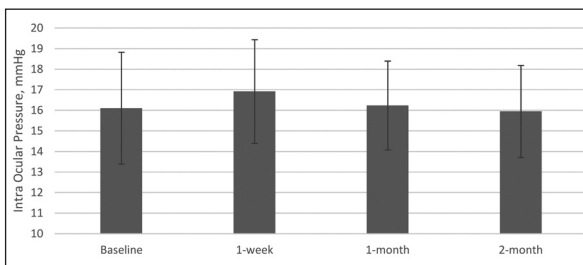
§ Change from previous control (Pairwise comparisons in repeated measures analysis of variance), $p = 0.05$.

†† Change from previous control (Pairwise comparisons in repeated measures analysis of variance), $p = 0.055$.

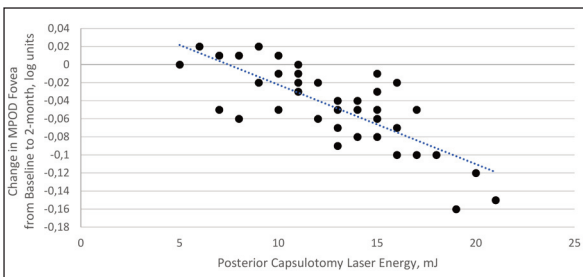
‡ Change from previous control (Pairwise comparisons in repeated measures analysis of variance), $p = 1$.



GRAPHIC 1: The mean values of best-corrected visual acuity during the study period. The marked lines mark the mean values for best-corrected visual acuity and intraocular pressure data set with the error bars showing the minimum and maximum values of all of the data, n=38, p<0.01.



GRAPHIC 2: The mean values of intraocular pressure during the study period. The mean values for best-corrected visual acuity and intraocular pressure data set are marked by the column bars with the error bars showing the minimum and maximum values of all of the data, n=38.



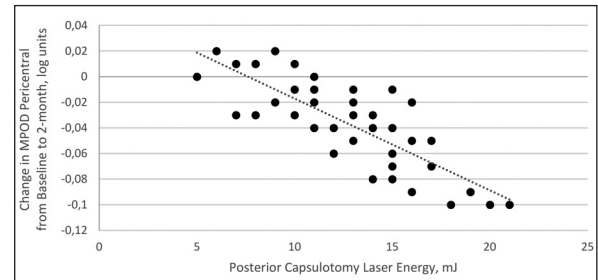
GRAPHIC 3: Correlations between applied energy of Nd:YAG laser and changes in MPOD fovea from baseline to 2-month. MPOD = macular pigment optical density. The applied laser energy significantly correlated with change in MPOD from baseline to 2-month (n=38, r = |-0.77|, p < 0.01). Line of best fit has been shown as a line through a scatter plot of data points.

after laser capsulotomy (p=0.04), and then it returned to baseline values (Graphic 2).

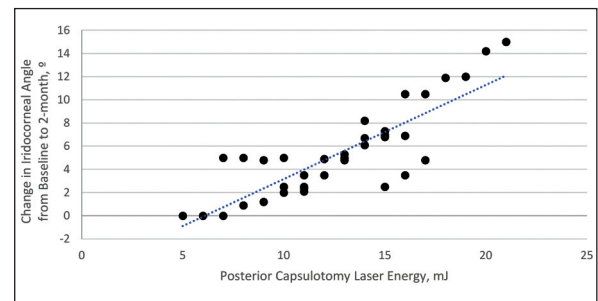
CORRELATIONS

The results of correlation analysis have shown significant relationships between applied energy in laser capsulotomy and the changes in MPOD in the fovea (Graphic 3) (Pearson’s correlation test, n=38, r=|-0.77|, p<0.001) and pericentral (Graphic 4) (Pear-

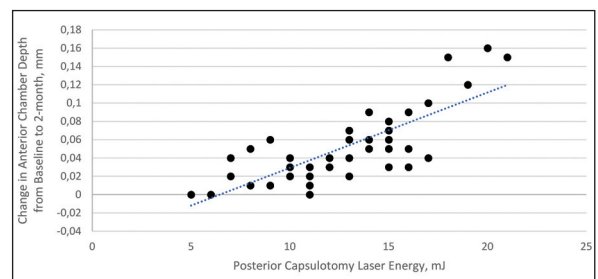
son’s correlation test, n=38, r=|-0.8|, p<0.001) regions, and the correlations between applied energy and the changes in iridocorneal angle (Graphic 5) (Pearson’s correlation test, n=38, r=0.84, p<0.001) as well as anterior chamber depth have also been seen (Graphic 6) (Pearson’s correlation test, n=38, r=0.78,



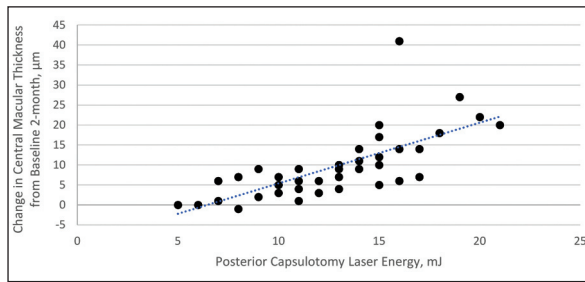
GRAPHIC 4: Correlation analysis shows significant negative relations between applied energy and the changes in MPOD in pericentral macular area for two months (n=38, r = |-0.8|, p < 0.01). MPOD = macular pigment optical density. Line of best fit has been shown as a line through a scatter plot of data points.



GRAPHIC 5: Correlations between applied energy of Nd:YAG laser and changes in iridocorneal angle from baseline to 2-month. The applied laser energy significantly correlated with change in the iridocorneal angle for two months (n=38, r=0.84, p<0.01). Line of best fit has been shown as a line through a scatter plot of data points.



GRAPHIC 6: Correlations between applied energy of Nd: YAG laser, and the changes in anterior chamber depth from baseline to 2-month. The applied laser energy significantly correlated with change in anterior chamber depth from baseline to 2-month (n=38, r=0.78, p<0.01). Line of best fit has been shown as a line through a scatter plot of data points.



GRAPHIC 7: Correlation between the applied total energy of Nd:YAG laser and the change in central macular thickness from baseline to 2-month. The applied total energy of Nd:YAG laser significantly correlated with the change in central macular thickness from baseline to 2-month ($n=38$, $r=0.71$, $p<0.01$). Line of best fit has been shown as a line through a scatter plot of data points.

$p<0.001$). The reductions in MPOD in the fovea and pericentral regions were proportionally much higher in patients who received higher doses of energy (Graphic 3, Graphic 4). Significant raises in iridocorneal angle and anterior chamber depth were in direct proportion to increased energy for two months (Graphic 5, Graphic 6). In addition to anterior chamber parameters, significant and positive correlations between the change of central macular thickness and applied energy were also observed in this study (Pearson's correlation test, $n=38$, $r=0.71$, $p<0.001$) (Graphic 7).

In addition to other correlation analyses, we also found a significant positive correlation between the intraocular pressure, which increased significantly at 1-week, and the change of iridocorneal angle at 1-week (Pearson's correlation test, $n=38$, $r=0.62$, $p<0.001$). Similar to the relationship between iridocorneal angle and intraocular pressure, there was also a significant correlation between the change of anterior chamber depth and intraocular pressure at 1-week (Pearson's correlation test, $n=38$, $r=0.58$, $p<0.001$). However, we have not seen a significant correlation between the change of MPOD in the fovea and the BCVA for two months ($n=38$, Spearman's rank correlation coefficient $\rho=0.13$ $p=0.46$).

DISCUSSION

Nd: YAG laser treatment remains the standard procedure for an intraocular lens with posterior capsule opacification, formed after cataract surgery. How-

ever, many side effects may occur after laser posterior capsulotomy. In addition to common side effects such as temporary intraocular pressure elevation or anterior chamber reaction, serious adverse effects may also be seen in the retina such as glaucoma, posterior vitreous detachment, cystoid macular edema or retinal detachment.^{4,5} Furthermore, there are also studies investigating the effect of Nd:YAG laser on choroidal thickness in the literature. In a study conducted by Yilmaz et al., an increase in the mean subfoveal choroidal thickness after the Nd: YAG laser has been seen, although not statistically significant.⁹ In another study, Yuvasi et al. have reported a non-significant increase in subfoveal choroidal thickness after Nd: YAG laser.⁸ In our study, significant increases were observed in the only nasal choroidal region, whereas temporary changes were observed in the subfoveal and temporal regions. There were temporary or nonsignificant changes in the choroidal thicknesses after laser procedure in the aforementioned studies.^{8,9} While temporary increases have been seen in the subfoveal and temporal areas also in our study; a significant increase has been observed only in the nasal choroidal thickness. The reason for this situation might be the lower energy content of the laser procedure performed in the previous study or the fluctuation of intraocular pressure induced by higher energy in our study. Those two studies and the previous studies examining the relationship between cataract surgery and choroid structure have suggested that postoperative inflammation may be responsible for increased choroidal thickness.⁸⁻¹¹ These results support the fact that inflammatory processes may assume an essential role in the change in choroidal thickness after Nd: YAG laser. As subfoveal and nasal areas are closer to the optical disc compared to the temporal region, the choroidal thickness change there requires more detailed studies concerning mechanisms.

Macular pigment is a critical antioxidant building in the retina that protects it against the harmful effects of high-energy visible blue light and its oxidant effects. MPOD is known to be affected by retinal diseases, particularly in age-related macular degeneration. However, the effect of the procedures, applied to the intraocular lens, on anterior chamber

parameters, along with MPOD, is a worthwhile investigation. A study showing increased oxidative stress in vitreous after laser capsulotomy supports the importance of macular pigment, which has an essential role concerning the prevention of oxidative stress.¹²

In our study, it has been seen that the mean MPOD continued to decrease for two months after the procedure. It is still debated whether this reduction is related to the thermal effect of the laser energy or the posterior capsule integrity. Investigating the ultraviolet and HEV lights' protective properties of the lens posterior capsule should be supported by another study, because the cause of the ongoing reduction may be due to disintegrated posterior capsule. However, the effect of laser energy on the retina should also be kept in mind. There are not many studies in the literature about the potential effect of laser energy on MPOD. The researchers have carried out many clinical trials about the effects of Nd: YAG laser on the retina for a long time. As expected, according to the results of the reports in the literature, similar to the previous YAG laser capsulotomy study, the mean central macular thickness has increased in similar values in our study.⁹ It is known that laser energy may cause edema in or around the macula, and the increase of the mean central macular thickness was in direct proportion to the applied laser energy in this study. The significant and correlated increase in the mean central macular thickness may support the direct effect of applied laser energy on MPOD. It is not very easy to distinguish whether this effect is due to the thermal effect of the laser or the vibration/reaction in the vitreous. The movement of posterior capsule fragments toward the vitreous gel after laser posterior capsulotomy is a known fact. The effect of the retinal changes caused by these fragments on MPOD can also be considered. The cases that large fragments occurred in those were excluded from the evaluation, and even though posterior capsule areas opened by laser were almost the same size in the cases, the reduction in the mean MPOD was in direct proportion to the applied laser energy in this study. This result supports that the decrease in MPOD may be more related to applied laser energy than the integrity of posterior capsule.

The color perimetry, previously mentioned in the method section, is an MPOD measurement technique developed in France and has a similar approach to heterochromatic flicker photometry. There is currently no standard gold method for MPOD measurement.¹³ However, heterochromatic flicker photometry is one of the most discussed methods in MPOD measurement. Although there has been debate about the gold standard in MPOD measurement, the decrease in MPOD for the only particular process was investigated in this study. Color perimetry and its associated method, heterochromatic flicker photometry, can be considered a reliable method to detect the change in MPOD for a particular process.¹³

As well as MPOD, we also evaluated the changes in anterior chamber depth and iridocorneal angle in this study. We have observed significant correlations between the laser energy, anterior chamber depth, and iridocorneal angle. In a study performed using anterior segment optical coherence tomography, Eliacik et al. have reported that the mean anterior chamber depth was 3.71 mm before laser capsulotomy in pseudophakic eyes.¹⁴ Al-Haddad has found that the mean anterior chamber depth was 3.61 mm before laser capsulotomy in that study.¹⁵ A study conducted in South Korea has reported that the mean ACD was 4.2 mm before Nd: YAG laser capsulotomy.¹⁶ The mean ACD before laser posterior capsulotomy was 3.7 mm in our study similar to the studies mentioned. As in all of these studies, the mean anterior chamber depth is increased after laser capsulotomy in our study.¹⁴⁻¹⁶ Increased mean anterior chamber depth may be explained by mild mechanical backward dislocation of the intraocular lens after the procedure. However, even though the posterior capsule areas opened by the laser were almost the same size, there was a significant correlation between the applied laser energy and the increase of anterior chamber depth. This result should make us think of the reasons other than a mechanical dislocation. One of the alternative reasons that should be considered is the possibility of structural changes in the intraocular lens after laser energy. Adhesion of vitreous gel to intraocular lens body induced by free posterior capsule fragments may cause slightly backward dislocation of the intraocular lens. It is thought that the

reason for the decrease in the mean iridocorneal angle is due to adhesions caused by the reaction in the iridocorneal angle region. The significant correlation between the applied laser energy and the iridocorneal angle contributes to this interpretation. Similar to the results in our study, Eliacik et al. and Al-Haddad have reported that they have observed increases in iridocorneal angle after YAG laser capsulotomy in their studies.^{14,15}

There were some limitations in this study. Firstly, although the number of samples was sufficient for statistical evaluation, a more extensive scale study could contribute more to the outcome of this study. Furthermore, the study with longer follow-up period could provide more detailed insight into the longer-term change of MPOD. Although our experience can show that this non-invasive and repeatable method can provide an idea for the change in MPOD for a particular process, the adoption of color perimetry or heterochromatic flicker photometry as the gold standard for MPOD measurement is still debated. Comparative follow-up, including other methods in MPOD measurement, can provide more detailed insight into this issue.

CONCLUSION

In conclusion, this study showed that MPOD has decreased after Nd: YAG laser posterior capsulotomy and the reduction continued for the following two months. Also, it has also been revealed that anterior chamber parameters were also affected. After laser procedure, it has been seen that the amount of laser

energy, applied to the intraocular lens, was correlated with recorded changes. The use of the least amount of energy in the treatment is essential for retinal side effects in Nd: YAG laser capsulotomy and the macular pigment. The use of a high amount of laser energy may make the retina to be sensitive to oxidant effects via macular pigment reduction and retinal adverse effects. Mechanical and structural changes in the intraocular lens may also contribute to this sensitivity.

Source of Finance

During this study, no financial or spiritual support was received neither from any pharmaceutical company that has a direct connection with the research subject, nor from a company that provides or produces medical instruments and materials which may negatively affect the evaluation process of this study.

Conflict of Interest

No conflicts of interest between the authors and / or family members of the scientific and medical committee members or members of the potential conflicts of interest, counseling, expertise, working conditions, share holding and similar situations in any firm.

Authorship Contributions

Idea/Concept: Bünyamin Kutluksaman; **Design:** Bünyamin Kutluksaman, Mustafa Doğan; **Control/Supervision:** Bünyamin Kutluksaman, Mustafa Doğan; **Data Collection and/or Processing:** Bünyamin Kutluksaman, Mustafa Doğan; **Analysis and/or Interpretation:** Bünyamin Kutluksaman, Mustafa Doğan; **Literature Review:** Bünyamin Kutluksaman, Mustafa Doğan; **Writing the Article:** Bünyamin Kutluksaman; **Critical Review:** Bünyamin Kutluksaman, Mustafa Doğan; **References and Fundings:** Mustafa Doğan; **Materials:** Mustafa Doğan.

REFERENCES

- Bhargava R, Kumar P, Sharma SK, Sharma S, Mehra N, Mishra A, et al. Peeling and aspiration of elsnig pearls! An effective alternative to Nd: YAG laser capsulotomy! Indian J Ophthalmol. 2013;61(9):518-20. [Crossref] [PubMed] [PMC]
- Sundelin K, Sjostrand J. Posterior capsule opacification 5 years after extracapsular cataract extraction. J Cataract Refract Surg. 1999;25(2):246-50. [Crossref]
- Auffarth G, Brezin A, Caporossi A, Lafuma A, Mendicute J, Berdeaux G, et al. Comparison of Nd: YAG capsulotomy rates following phacoemulsification with implantation of PMMA, silicone, or acrylic intra-ocular lenses in four European countries. Ophthalmic Epidemiol. 2004;11(4):319-29. [Crossref] [PubMed]
- Channell MM, Beckman H. Intraocular pressure changes after neodymium-YAG laser posterior capsulotomy. Arch Ophthalmol. 1984;102(7):1024-6. [Crossref] [PubMed]
- Billotte C, Berdeaux G. Adverse clinical consequences of neodymium: YAG laser treatment of posterior capsule opacification. J Cataract Refract Surg. 2004;30(10):2064-71. [Crossref] [PubMed]
- Slomovic A, Parrish R. Acute elevations of intraocular pressure following Nd:Yag laser posterior capsulotomy. Ophthalmology. 1985;92(7):973-6. [Crossref]
- Park J, Son Y, Lee S. Macular hole formation and spontaneous closure following neodymium-doped yttrium aluminum garnet capsulotomy in a vitrectomized eye. Indian J Ophthalmol. 2016;64(2):165-6. [Crossref] [PubMed] [PMC]
- Yuvaci I, Pangal E, Yuce Y, Yuvaci S, Bayram N, Ulusoy DM, et al. Optic coherence tomography measurement of choroidal and retinal thicknesses after uncomplicated YAG laser capsulotomy. Arq Bras Oftalmol. 2015;78(6):344-7. [Crossref] [PubMed]

9. Yilmaz T, Yilmaz A. Long-term changes in subfoveal choroidal thickness and central macula thickness after Nd:YAG laser capsulotomy. *Int Ophthalmol.* 2017;37(4):1003-8. [[Crossref](#)] [[PubMed](#)]
10. Noda Y, Ogawa A, Toyama T, Ueta T. Long-term increase in subfoveal choroidal thickness after surgery for senile cataracts. *Am J Ophthalmol.* 2014;158(3):455-9.e1. [[Crossref](#)] [[PubMed](#)]
11. Ohsugi H, Ikuno Y, Ohara Z, Imamura H, Nakakura S, Matsuba S, et al. Changes in choroidal thickness after cataract surgery. *J Cataract Refract Surg.* 2014;40(2):184-91. [[Crossref](#)] [[PubMed](#)]
12. Bergandi L, Skorokhod OA, Franzoni F, La Grotta R, Schwarzer E, Nuzzi R, et al. Induction of oxidative stress in human aqueous and vitreous humors by Nd:YAG laser posterior capsulotomy. *Int J Ophthalmol.* 2018;18;11(7):1145-51.
13. Creuzot-Garcher C, Koehrer P, Picot C, Aho S, Bron AM. Comparison of two methods to measure macular pigment optical density in healthy subjects. *Invest Ophthalmol Vis Sci.* 2014;2;55(5):2941-6. [[Crossref](#)] [[PubMed](#)]
14. Eliaçık M, Bayramlar H, Erdur SK, Demirci G, Gülkılık K. Anterior segment optical coherence tomography measurement after neodymium-yttrium-aluminum-garnet laser capsulotomy. *Am J Ophthalmol.* 2014;158(5):994-8. [[Crossref](#)] [[PubMed](#)]
15. El-Haddad M, El-Dien NS. The impact of Nd:YAG laser posterior capsulotomy by the use of "the circular pattern with vitreous strand cut" technique on anterior chamber parameters. *Lasers Med Sci.* 2019;34(2):353-7. [[Crossref](#)] [[PubMed](#)]
16. Shin MH, Kang HJ, Kim SJ, Chung IY, Seo SW, Yoo JM, et al. Effect of Nd:YAG laser capsulotomy on anterior segment parameters in patients with posterior capsular opacification after phacovitrectomy. *Korean J Ophthalmol.* 2018;32(5):369-75. [[Crossref](#)] [[PubMed](#)] [[PMC](#)]