

Understanding What You Have Found: A Family With a Mutation in the *LAMA1* Gene With Literature Review

Muhsin Elmas , Basak Gogus and Mustafa Solak

Medical Genetics Department, Afyonkarahisar Health Sciences University, Afyonkarahisar, Turkey.

Clinical Medicine Insights: Case Reports
Volume 13: 1–6
© The Author(s) 2020
Article reuse guidelines:
sagepub.com/journals-permissions
DOI: 10.1177/1179547620948666



ABSTRACT

INTRODUCTION: Cerebellar dysplasia with cysts (CDC) is an imaging finding which is typically seen with in individuals with dystroglycanopathy. One of the diseases causing this condition is “Poretti-Boltshauser Syndrome; PTBHS” (OMIM #615960). Homozygous or compound heterozygous mutations in the *LAMA1* gene cause this disease.

CASE PRESENTATION: 7 years old twin siblings consulted to the medical genetics department because of walking problems and cerebellar examination findings.

MANAGEMENT AND OUTCOME: Clinical and radiological findings of the patient suggested a syndrome with recessive inheritance. Whole exome sequencing (WES) test was performed for definitive diagnosis. As a result of the patient’s WES analysis, a homozygous mutation was detected in the *LAMA1* gene.

DISCUSSION: When determining the inheritance pattern of genetic diseases, if parents have consanguinity, this situation leads us to recessive inheritance diseases. Even if we are not consanguinity, but they say the same village, it is necessary to pay attention to the diseases of the recessive group. Whole exome sequencing analysis results in large amount of data generation. A good clinical evaluation is required to detect the mutation as a result of large data. To understand what we have found, we need to know what we are looking for.

KEYWORDS: Cerebellar vermis, cerebellar ataxia, laminin

RECEIVED: November 27, 2019. **ACCEPTED:** December 19, 2019.

TYPE: Case Report

FUNDING: The author(s) received no financial support for the research, authorship, and/or publication of this article.

DECLARATION OF CONFLICTING INTERESTS: The author(s) declared no potential conflicts of interest with respect to the research, authorship, and/or publication of this article.

CORRESPONDING AUTHOR: Muhsin Elmas, Medical Genetics Department, Afyonkarahisar Health Sciences University, Afyonkarahisar, Turkey. Email: drmelmas@gmail.com

Introduction

Cerebellar malformations cause defective development of the cerebellum and often manifest itself in the first months of life. For some cerebellar malformations, neuroimaging findings are specific and provide diagnosis of disease.¹ However, imaging findings of other cerebellar malformations such as hypoplasia, dysplasia, and cysts are less specific for the disease in which they are components.^{2,3} In 2014, “Poretti-Boltshauser Syndrome; PTBHS” (OMIM #615960) is defined by cerebellar cyst and cerebellar dysplasia.⁴ This disease also causes myopia with or without retinal dystrophy.

Laminins connect basal membranes and extracellular matrix to cell and these are heterotrimeric glycoproteins. At the same time their function is to provide the integrity of the tissue.⁵ Of the 12 genes, 9 encoding the laminin subunits are associated with the disease in human.^{6–8} One of these genes is the *LAMA1* gene encoding Laminin alpha-1. The mutation in this gene causes congenital muscular dystrophy group diseases. In 2014, in the study by Aldinger et al., homozygous or compound heterozygous mutations in this gene were reported to cause “PTBHS.”⁴

This disease is very rare. A total of 31 cases (we think 2 of them are repeated and same cases and therefore total number may be 29) of PTBHS have been reported in 4 publications.^{4,9–13} In this case report, we aimed to present the clinical findings of

the siblings with homozygous mutations in the *LAMA1* gene that caused PTBHS.

Case Presentation

Twin boys aged 7 years consulted the medical genetics department with walking problem and cerebellar examination findings. Anamnesis information, examination findings, laboratory results, and genetic test results of twins are summarized in the following.

Patient 1

He was born at 38 weeks of gestation as 2300 g. The 5-minute APGAR score was 8 to 9 points. He started walking at 2 years. At physical examination, head circumference, height, and weight were between 10 and 25 percentile. At the dysmorphic examination, narrow face, pointed chin, hypertelorism, telecanthus, macrotia, smooth philtrum, and thin upper lip vermilion were found. Hypokinesia and dysmetria were detected in the cerebellar examination of the patient. Also, he had ataxia when walking. At ophthalmic examination, he had normal fundus and he had no visual problems. The pathological findings at magnetic resonance imaging (MRI) of the patient are as follows: multiple cysts in millimetric dimensions at both cerebellar hemispheres, irregularities in the cerebellum cortex,



Table 1. Summary of the literature of the cases of Poretti-Boltshauser Syndrome and our cases.

ALDINGER ET AL ⁴							
	P1	P2	P3	P4	P5	P6	P7
Age	36 months	36 months	25 months	29 years	23 years	5.5 years	4.5 years
Sex	Female	Female	Male	Female	Male	Female	Female
In <i>LAMA1</i> gene							
Zygosity	Homozygous	Compound heterozygous	Compound heterozygous	Compound heterozygous	Compound heterozygous	Compound heterozygous	Compound heterozygous
Mutation	c.588+2T>G	c.6345+3G>C (maternal) and deletion of exons 4-11 (paternal)	c.7965-15_7965-3del (paternal) and c.2988_2989delA (maternal)	c.6701delC (paternal) and c.8557-1G>C, c.768+1G>A (maternal)	c.6701delC (paternal) and c.8557-1G>C, c.768+1G>A (maternal)	c.2816_2817delAT (paternal) and c.555T>G (maternal)	c.2816_2817delAT (paternal) and c.555T>G (maternal)
Protein change	Canonical splice	Splice and NA	Splice and p.Pro996Hisfs28*	p.Pro2334Leufs9* and splice, splice	p.Pro2334Leufs9* and splice, splice	p.Tyr939Leufs27* and p.Tyr185*	p.Tyr939Leufs27* and p.Tyr185*
Ethnicity	Iranian	Mixed European	Mixed European	Mixed European	Mixed European	Asian and African American	Asian and African American
Occipitofrontal circumference	50th percentile	>98th percentile	20th percentile	50th percentile	30th percentile	35th percentile	35th percentile
Neurodevelopmental features	Moderate motor and speech delay	Moderate motor delay (no standing or walking), mild speech delay	Motor delay (cruising, but no walking), hypotonia	History of motor delay, normal speech, normal IQ, college graduate, lives independently	History of motor and speech delay, normal IQ, autism spectrum disorder (Asperger), lives with parents	Mild motor and speech delay, hypotonia	Motor and speech delay, hypotonia
Ataxia	Unknown	Unknown	Unknown	Unknown	Unknown	Unknown	Unknown
Autistic features	-	-	-	-	-	-	-
Strabismus	+	+	+	+	+	-	+
<i>Brain MRI</i>							
Cerebellar dysplasia	+	+	+	+	+	+	+
Cerebellar cysts	+	+	+	+	+	-	-
Vermis hypoplasia	Global	Global	Global	Global	Global	Inferior only	Inferior only
Superior cerebellar peduncles	Elevated and splayed	Elevated and splayed	Normal	Elevated and splayed	Elevated and splayed	Normal	Slightly elevated
Fourth ventricle	Enlarged	Enlarged	Enlarged	Enlarged	Enlarged	Mildly enlarged	Normal
Brainstem	Short pons, thin isthmus	Short pons, long midbrain, mildly enlarged tectum	Normal	Thin isthmus	Thin isthmus	Mass effect from arachnoid cyst	Normal
Ventricles	Normal	Moderate ventriculomegaly, partial agenesis of corpus callosum and septum pellucidum	Normal	Normal	Normal	Normal	Normal
Increased T2/FLAIR in white matter	Patchy increased, periventricular	Patchy increased, periventricular	Normal	Normal	Normal	Patchy increased, periventricular	Normal
Other	Atrophic retina, aminoaciduria, consanguinity	Thinned retina, seizure	Absent pigment at retina	Lattice and peripheral degeneration at retina, macular heterotopia, increased pigment at retina, fatty liver on ultrasound, syndactyly in second and third toes	Atrophic retina, bilateral cataracts, echogenic liver on ultrasound, syndactyly in second and third toes	Retinal dysfunction: cones more affected than rods	Chorioretinal atrophy, macular and peripheral involvement, cones worse than rods

Abbreviation: MRI, magnetic resonance imaging.

VILBOUX ET AL ¹⁰			MARLOW ET AL ¹¹		MASSON ET AL ¹²	BANERJEE ET AL ¹³	OUR CASES	
P1	P2	P3	P1	P2	P1	P1	P1	P2
21 years	26 years	8,5 years	Younger than 5 years	Younger than 5 years	30 months	2.5 years	7 years	7 years
Male	Female	Female	Female	Male	Female	Male	Male	Male
Compound heterozygous	Compound heterozygous	Compound heterozygous	Compound heterozygous	Compound heterozygous	Compound heterozygous	Homozygous	Homozygous	Homozygous
c.6701delC (paternal) and c.768+1G>A, c.8557-1G>C (maternal)	c.6701delC (paternal) and c.768+1G>A, c.8557-1G>C (maternal)	c.2160T>A (maternal) and c.5985_5991del (paternal)	c.664C>T and c.2331C>G	c.664C>T and c.2331C>G	—	c.4702_4703del	c.8192C>A	c.8192C>A
Canonical splice and Pro2234Leufs*9	Canonical splice and Pro2234Leufs*9	p.Cys720* and p.Ile1996Gluufs*7	p.Arg222* and p.Tyr777*	p.Arg222* and p.Tyr777*	p.R2921* and exon 62-63 deletion	p.(Leu1568 Glyfs*2)	(p.S2731*) (p.Ser2731 Ter)	(p.S2731*) (p.Ser2731Ter)
Unknown	Unknown	Caucasian and Native American	Unknown	Unknown	Caucasian	Unknown	Turkish	Turkish
Normal	Normal	Unknown	Unknown	Unknown	Unknown	<3 percentile	10-25 percentile	<3 percentile
History of motor and speech delay, graduated high school, mildly wide-based gait	Mild motor and speech delays, mildly wide-based gait, graduated from high school	Delayed motor development	Delayed	Delayed	Mild motor delay	Delayed	Mild motor delay, hypokinesia and dysmetria	Mild motor and speech delays
+	+	+	Unknown	Unknown	+	+	+	Unknown
-	-	-	Unknown	Unknown	+	Unknown	-	-
+	+		Unknown	Unknown	-	Unknown		+
+	+	+	+	+	+	+	+	The patient has no MRI
+	+	+	+	+	+	+	+	
+	+	Global	-	-	+	-	+	
Normal	Normal	Normal	Atrophic	Atrophic	Normal	-	Normal	
Enlarged	Enlarged	Normal	Enlarged	Enlarged	Enlarged	Enlarged	Enlarged	
Midbrain is mildly elongated, pons is mildly reduced	Elongated midbrain and pons and appearing small	Normal	Normal	Normal	Normal	Unknown	Normal	
Normal	Normal	Normal	Normal	Normal	Normal	Unknown	Normal	
Normal	Normal	Normal	Normal	Normal	Normal	Bilateral peritrigonal periventricular white matter changes	Normal	
Retinal dystrophy, high myopia, shoulder shrugging and nose wrinkling tics, bilateral syndactyly of the second and third toes	Shoulder shrugging and nose wrinkling, bilateral syndactyly of the second and third toes	Peripheral lattice degeneration of retina and bilateral arm extensions and flexions, nose wrinkling tics	High myopia	High myopia	Head titubation, occasional motor stereotypes, ocular motor apraxia	Myopia	Normal	Encephalocele, spasticity, pale optic disk

cerebellar vermis hypoplasia, and enlargement at fourth ventricle (Figures 1 and 2).

Patient 2

In the prenatal period, encephalocele was detected in the seventh month of pregnancy. He was born at 38 weeks of gestation as 1900 g. The 5-minute APGAR score was 6 to 7 points. The encephalocele was excised at 16th day postnatal. The brain tissue and optic nerve were also located in this sac, so these structures were excised too. Hence, he is blind. He had ventriculoperitoneal shunt operation at the ninth month. When he was 5 years old, Botox was injected at the ankles because of spasticity in the lower extremities and tension in the Achilles tendon. He cannot walk still. At physical examination of the patient, his head circumference, height, and weight were under 3 percentile. He had microcephaly. His neck movement had limited extension. At the upper and lower extremities, he had spasticity. At the dysmorphic examination, narrow face, malar flattening, hypertelorism, upslanted palpebral fissure, telcanthus, macrotia, smooth philtrum, and thin upper lip vermillion were found. At ophthalmic examination, he had pale optic disk at the temporal regions in both eyes and he cannot see. At his cranial computed tomography, it was observed that lateral ventricles and third ventricular were collapsed.

The parents of these twin siblings have no consanguinity, but they are from the same village.

Whole exome sequencing (WES) was performed. As a result of this analysis, the homozygous NM_005559.4 c.8192C>A (p.S2731*) (p. Ser2731Ter) VCV000372974.1 in the *LAMA1* gene was detected (ClinVar ID is RCV000413473.1). This mutation is classified as disease causing in MutationTaster and the allele frequency is 0.0000159. In the analysis of the parents, the same mutation was resulted as heterozygous and these were again confirmed by Sanger sequencing. According to the American College of Medical Genetics (ACMG) criteria, this mutation has been reported as "pathogenic." This is called "PTBHS" (OMIM #615960). Because of the genotype-phenotype similarity of the patients in the literature and our patients, we decided that the diagnosis was PTBHS. Thus, the definitive diagnosis was provided for twin brothers.

Additional informed consent was obtained from all individual participants for whom identifying information is included in this article. Ethical approval is not required at our institution to publish an anonymous case report.

Discussion

A total of 12 cases were reported in three publications for PTBHS (summarized in Table 1). Previously, in the study of Micalizz et al., PTBHS patients from Turkey have been reported. We did not include Table 1 because they did not evaluate patients one by one in their articles. In addition, Table 2 summarizes the clinical and MRI findings of patients including the study of Micalizzi et al.

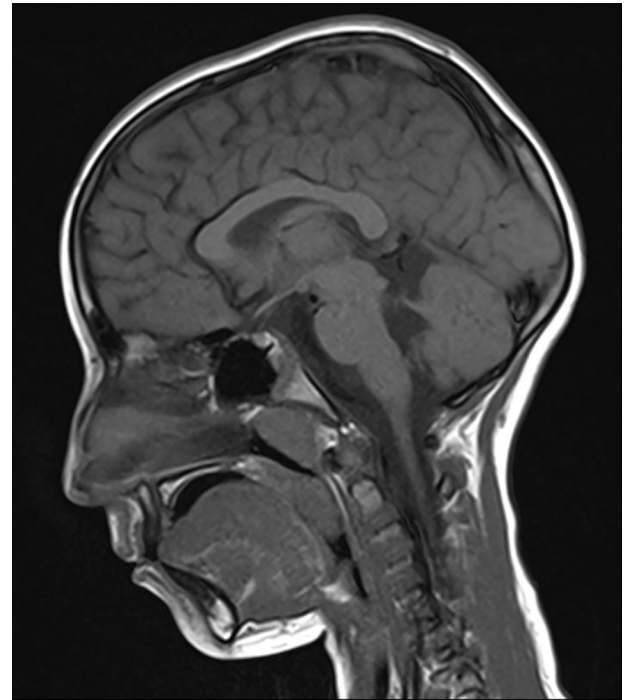

Figure 1. Brain MR images show cerebellar cyst and enlarged fourth ventricle. MR indicates magnetic resonance.

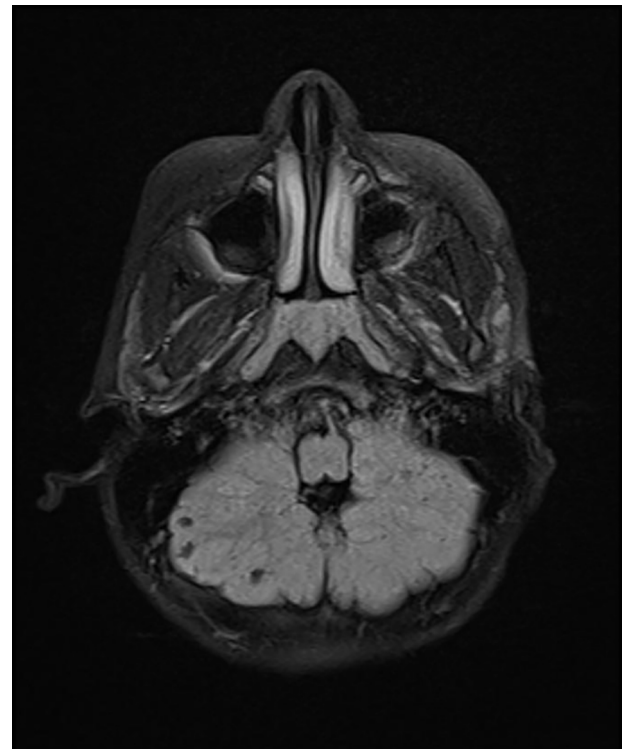


Figure 2. Brain MR images show cerebellar cyst. MR indicates magnetic resonance.

Previously, cases who are siblings have been reported, but identical twins cases have not been reported and encephalocele finding was also not previously reported in any cases. That may be wrong to think that *LAMA1* gene mutation may be the possible cause of encephalocele finding in P2. Because there is an

Table 2. Clinical and MRI features of cases reported as PTBHS (including our twin patients).

FEATURES	NUMBER OF PATIENTS (%)
Sex (female)	16 of 33 (48)
Ataxia	22 of 33 (67)
Strabismus	17 of 33 (52)
Neurodevelopmental delay	32 of 33 (97)
Myopia	12 of 33 (36)
Retinal dystrophy	15 of 33 (45)
Cerebellar dysplasia	32 of 33 (97)
Cerebellar cysts	31 of 33 (94)
Enlarged fourth ventricle	27 of 33 (82)
Abnormal brainstem	15 of 33 (45)

Abbreviation: PTBHS, Poretti-Boltshauser Syndrome; MRI, magnetic resonance imaging.

increased risk of congenital cranial malformations in twin cases.^{14,15}

The compound heterozygous mutation is mostly observed. Previously, only one case reported had a homozygous mutation. At that case, consanguinity between parents was reported. Homozygous mutation was found in our cases too, but their parents had no consanguinity between. However, they were born in the same village. This situation suggests that they have consanguinity from distant ancestors. Therefore, it is very important to ask the patients where their parents are from. Because if they are from the same village, recessive inheritance disease should be considered.

At eye examination, most of the patients were found to have eye findings. At the eye examination, in one of our patients, any findings were found (P1). The possible cause of this condition can be considered as this mutation damage eyes less than other mutations. The probable cause of ocular finding in the other twin is encephalocele which develops during intrauterine period.

All mutations in a gene that cause a disease do not cause the same clinical findings due to mechanisms such as allelic heterogeneity and variable expressivity in genetic diseases. As shown in Table 1, the age at which PTBHS patients are diagnosed is on a wide range from 25 months to 29 years. The mean age of the patients presented in Table 1 (except our patient) was 10.10. In addition, Micalizzi et al. reported that the average age of follow-up of 17 patients with PTBHS was 7.2 years.⁹ MRI findings are present in almost all patients. However, eye examination findings and clinical findings such as ataxia and microcephaly were not reported in all the patients. This situation is an example for a genetic disease that causes a variety of clinical effects even in mutations in the same gene. As

seen in our twin patients, although they have the same mutation but their severity for disease are different. Patients with mild clinical findings or with rare clinical findings in the disease may be challenging in diagnosis. In such a case, WES may be a preferable test.

Conclusions

The penetrance of all genetic diseases is different. This makes the diagnosis difficult. It is important to know the patient's clinical history very well and to evaluate the patient in a multi-disciplinary manner.

Acknowledgements

We thank our patient for agreeing to this report and sharing their insights on the genetic counselling experience.

Author Contributions

ME conceived and designed the study. BG performed clinical assessments. ME performed experiments and contributed to data acquisition, analysis, and interpretation. BG and MS drafted the manuscript. All authors contributed to critical revision of the manuscript for intellectual content and final approval of the manuscript.

Consent for Publication

Written informed consent was obtained from the patient's parents for publication of this case report. A copy of the written consent is available for review by the Editor-in-Chief of this journal. The family and patient agree to publish this paper and have read and approved the final version of this manuscript including photos of the patient.

Ethical Approval

Ethical approval is not required at our institution to publish an anonymous case report.

ORCID iD

Muhsin Elmas  <https://orcid.org/0000-0002-5626-2160>

REFERENCES

1. Bosemani T, Orman G, Boltshauser E, Tekes A, Huisman TAGM, Poretti A. Congenital abnormalities of the posterior fossa. *Radiographics*. 2015;35:200-220. doi:10.1148/rg.351140038.
2. Boltshauser E, Scheer I, Huisman TAGM, Poretti A. Cerebellar cysts in children: a pattern recognition approach. *Cerebellum*. 2015;14:308-316. doi:10.1007/s12311-014-0633-9.
3. Poretti A, Boltshauser E, Doherty D. Cerebellar hypoplasia: differential diagnosis and diagnostic approach. *Am J Med Genet C Semin Med Genet*. 2014;166C:211-226. doi:10.1002/ajmg.c.31398.
4. Dempsey JC, Aldinger KA, Mosca SJ, et al. Mutations in LAMA1 cause cerebellar dysplasia and cysts with and without retinal dystrophy. *Am J Hum Genet*. 2014;95:227-234. doi:10.1016/j.ajhg.2014.07.007.
5. Li S, Liqari P, McKee KK, et al. Laminin-sulfatide binding initiates basement membrane assembly and enables receptor signaling in Schwann cells and fibroblasts. *J Cell Biol*. 2005;169:179-189. doi:10.1083/jcb.200501098.
6. Sewry CA, Philpot J, Mahony D, Wilson LA, Munttoni F, Dubowitz V. Expression of laminin subunits in congenital muscular dystrophy. *Neuromuscul Disord*. 1995;5:307-316.

7. Hasselbacher K, Wiggins RC, Matejas V, et al. Recessive missense mutations in LAMB2 expand the clinical spectrum of LAMB2-associated disorders. *Kidney Int.* 2006;70:1008-1012. doi:10.1038/sj.ki.5001679.
8. Mundegar RR, von Oertzen J, Zierz S. Increased laminin A expression in regenerating myofibers in neuromuscular disorders. *Muscle Nerve.* 1995;18:992-999. doi:10.1002/mus.880180911.
9. Micalizzi A, Poretti A, Romani M, et al. Clinical, neuroradiological and molecular characterization of cerebellar dysplasia with cysts (Poretti-Boltshauser syndrome). *Eur J Hum Genet.* 2016;24:1262-1267. doi:10.1038/ejhg.2016.19.
10. Vilboux T, Malicdan MCV, Chang YM, et al. Cystic cerebellar dysplasia and biallelic LAMA1 mutations: a lamininopathy associated with tics, obsessive compulsive traits and myopia due to cell adhesion and migration defects. *J Med Genet.* 2016;53:318-329. doi:10.1136/jmedgenet-2015-103416.
11. Marlow E, Chan RVP, Oltra E, Rusu I, Gupta MP. Retinal avascularity and neovascularization associated with LAMA1 (laminin1) mutation in Poretti-Boltshauser syndrome. *JAMA Ophthalmol.* 2018;136:96-97. doi:10.1001/jamaophthalmol.2017.5060.
12. Masson R, Piretti E, Pellegrin S, et al. Early-onset head titubation in a child with Poretti-Boltshauser syndrome. *Neurology.* 2017;88:1478-1479. doi:10.1212/WNL.0000000000003823.
13. Banerjee A, Vyas S, Sankhyan N. Cerebellar cysts and dysplasias: more diagnoses to consider. *Pediatr Neurol.* 2019;98:91-92. doi:10.1016/j.pediatrneurol.2019.02.021.
14. Sepulveda W, Wong AE, Andreeva E, Odegova N. Sonographic spectrum of first-trimester fetal cephalocele: review of 35 cases. *Ultrasound Obstet Gynecol.* 2015;46:29-33. doi:10.1002/uog.14661.
15. Kar A, Nanda S, Kar T, Dhal I, Satpathy BP, Mohapatra K. Prevalence and spectrum of congenital anomalies in multiple births with analysis of demographic and obstetric risk factors. *Obstet Gynecol.* 2018;12:5-9. doi:10.7860/JCDR/2018/32531.12032.