

See discussions, stats, and author profiles for this publication at: <https://www.researchgate.net/publication/359078722>

Assessment of retinal, choroidal and retinal nerve fiber layer thicknesses in inflammatory bowel diseases

Article in *Journal of Retina-Vitreous* · January 2022

DOI: 10.37845/ret.vit.2022.31.2

CITATIONS

0

READS

56

6 authors, including:



Mustafa Doğan

Afyonkarahisar Sağlık Bilimleri Üniversitesi

115 PUBLICATIONS 522 CITATIONS

SEE PROFILE



Mehmet Cem Sabaner

63 PUBLICATIONS 164 CITATIONS

SEE PROFILE



Elif Ertan Baydemir

Başakşehir Çam Sakura City Hospital

22 PUBLICATIONS 40 CITATIONS

SEE PROFILE

Assessment of Retinal, Choroidal and Retinal Nerve Fiber Layer Thicknesses in Inflammatory Bowel Diseases

Mustafa Doğan¹, Serkan Özcan², Gürsel Acartürk³, Mehmet Cem Sabaner⁴, Elif Ertan⁵, Mehmet Akif Seylan⁶

ABSTRACT

Purpose: To compare the thickness of macula, choroid, and peripapillary retina nerve fiber layer (RNFL) in patients with inflammatory bowel disease (IBD).

Materials and Methods: 57 patients with IBD and 29 healthy individuals evaluated for this cross-sectional study. Macular thickness (MT), RNFL thickness, and choroidal thickness (CT) were measured by SD-OCT.

Results: Twenty-six eyes of 26 Crohn's disease (CD) patients, thirty-one eyes of 31 ulcerative colitis (UC) patients, and twenty-nine eyes of 29 healthy subjects as control group were included in the study. There was no significant difference between groups in age and sex (p:0.696 and p:0.115, respectively). The evaluations in all of the macular thickness, choroidal thickness, RNFL show no significant difference between the IBD and control subjects.

Conclusion: Inflammatory bowel diseases such as Crohn's disease and ulcerative colitis have no change in the choroid, RNFL, and macular thickness. Further studies are needed.

Keywords: Crohn's disease, Ulcerative colitis, Retina, Choroid, Retinal nerve fiber layer.

INTRODUCTION

Inflammatory bowel disease (IBD), including Crohn's disease (CD) and ulcerative colitis (UC), is a chronic inflammatory disorder of unknown etiology which primarily involves the intestine.^{1,2} Extraintestinal complications frequently occur during the course of the disease, and the eye is involved in 4 to 10 % of IBD patients.¹ The ophthalmic complications are usually of inflammatory origin. Possible ophthalmological findings are periocular edema, blepharitis, proptosis, conjunctivitis, scleritis, episcleritis, keratopathy, cataract, optic neuritis, optic neuropathy, iridocyclitis, retinal pigment epithelial atrophy, macular edema, serous retinal detachment and retinal hemorrhages.³⁻⁷ Retinal vascular involvement like vasculitis and vascular occlusion are relatively common retinal findings.

Spectral-domain optical coherence tomography (SD-OCT) is a noninvasive method for studying retinal layer structures in a range of retinal conditions.⁸ Recently, SD-OCT, termed enhanced depth imaging (EDI), has been shown to be capable of visualizing the full thickness of the choroid. Changes in choroidal and retinal thickness have previously been reported in a number of autoimmune and systemic inflammatory disorders.^{9,10} This study aimed to compare the thickness of the macula, choroid, and peripapillary retina nerve fiber layer (RNFL) in patients with inflammatory bowel disease, healthy individuals using spectral-domain optical coherence tomography (SD-OCT).

MATERIALS AND METHODS

This cross-sectional study was performed in the Department of Ophthalmology of the Afyonkarahisar University of

1- Associate Professor, MD, Afyonkarahisar Health Sciences University, Department of Ophthalmology, Afyonkarahisar, Türkiye

2- Ophthalmologist, İdil State Hospital, Department of Ophthalmology, Şırnak, Türkiye

3- Prof. Dr., MD, Private Office, Department of Gastroenterology, Afyonkarahisar, Türkiye

4- Ophthalmologist, Bafra State Hospital, Department of Ophthalmology, Samsun, Türkiye

5- Ophthalmologist, Gaziosmanpaşa Research and Training Hospital,, Department of Ophthalmology, İstanbul, Türkiye

6- Ophthalmologist, Kanuni Sultan Süleyman Research and Training Hospital, Department of Ophthalmology, İstanbul, Türkiye

Received: 21.03.2021

Accepted: 11.11.2021

Ret-Vit 2022; 31: 4-8

DOI:10.37845/ret.vit.2022.31.2

Correspondence Address:

Mustafa Doğan

Afyonkarahisar Health Sciences University, Department of Ophthalmology, Afyonkarahisar, Türkiye

Phone:

E-mail: mustafadogan@yahoo.com

Health Sciences Faculty of Medicine (Afyonkarahisar, Turkey). This study was approved by the Afyonkarahisar University of Health Sciences Faculty institutional review board and ethics committee and was conducted in accordance with the tenets of the Declaration of Helsinki. Informed consent was obtained from all patients.

Age and gender matched healthy individuals were included in the study. The criteria for inclusion in the study included spherical refraction between +1.0 and -1.0 diopters, best-corrected visual acuity of 20/20 or better, and 21 mm < axial length < 25 mm. Slit-lamp biomicroscopy, fundus examination, and SD-OCT were evaluated. None of the patients had evidence of previous or active uveitis. Inflammatory bowel disease group patients were diagnosed based on colonoscopy or rectosigmoidoscopy and other tests (complete blood cell count, vitamin B12 evaluation, iron studies, and red blood cell folate) in gastroenterology department. They were still on prescribed therapies. All patients were diagnosed by biopsy and pathology results at the gastroenterology clinic. All patients were using orally sulfasalazine treatment initiated by gastroenterology.

After pupil dilatation with tropicamide 1% (Alcon, Rødovre, Denmark), all patients underwent SD-OCT imaging by the Spectralis (Heidelberg Engineering Germany). All SD-OCT images were obtained by the same investigator at 9.00 to 12.00 AM. The choroid thicknesses (CT) were imaged using the enhanced depth imaging (EDI) technique with spectral-domain OCT. Five measurements (one subfoveal, two temporal, and two nasal) were noted at central, 1000 μm intervals up to 2000 μm via the software caliper (Figure 1). Peripapillary retina nerve fiber layer thickness was automatically measured from the system software using the optical disc RNFL mode. The thicknesses of RNFL in the global, inferior, superior, nasal and temporal regions were noted. The macular thickness (MT) was measured automatically from the software of the system using the macular examination mode. The all of macular thicknesses determined according to the rings determined according to ETDRS were noted. All measurements were made between 09:00 and 10:00 AM by a single observer blinded (EE).

Statistical Analysis

Statistical analysis was performed using the statistical package for social science, SPSS version 18 (SPSS, Inc., Chicago, IL). The normality of the distribution of quantitative variables was determined with the Shapiro-Wilk test. Descriptive statistics were expressed with mean \pm SD and ratio. To compare variables between groups, the one-way ANOVA test was used for normally distributed variables. $p < 0.05$ was considered statistically significant.

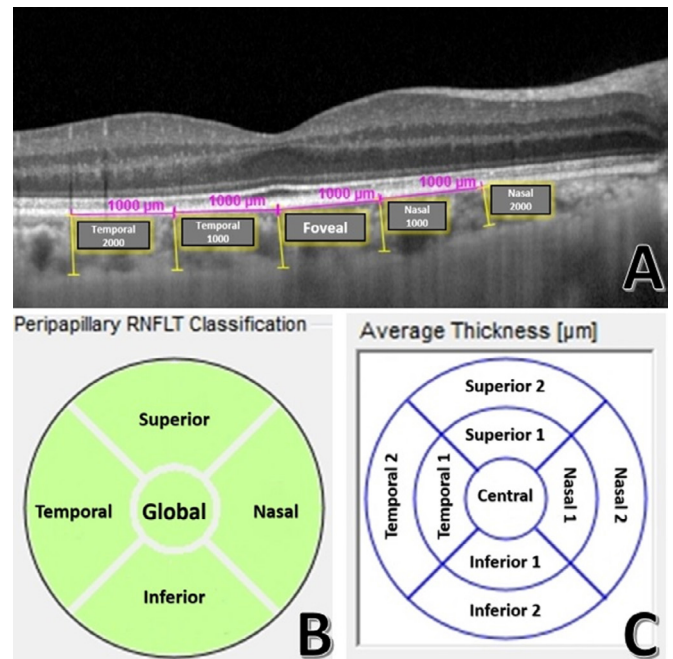


Figure 1: A: The five choroidal thickness measurements (one subfoveal, two temporal, and two nasal) were noted semi-automatic at central, 1000 μm intervals up to 2000 μm via the software caliper in SD-OCT: EDI mode. B: The thicknesses of RNFL in the global, inferior, superior, nasal and temporal regions were noted. C: The macular thicknesses (nine regions) for determined according to the rings determined according to ETDRS were noted.

RESULTS

The study included twenty-six eyes of 26 CD patients, thirty-one eyes of 31 UC patients, and twenty-nine eyes of 29 healthy control subjects. The mean ages of Crohn's disease patients (n:26, 10 female, 16 male) was 44.2 ± 12.30 years, ulcerative colitis patients (n:31, 9 female, 22 male) was 44.45 ± 11.35 years, and controls (n:29, 16 female, 13 male) were 42.06 ± 12.88 years. There was no significant difference between these groups with respect to age and sex ($p:0.696$ and $p:0.115$, respectively).

The mean duration of the disease in ulcerative colitis was 5.35 ± 3.01 years (range 2-15 years) and 4.50 ± 2.25 years (range 2-10 years) for those with Crohn's disease (Table 1). There was no significant difference between these groups with respect to the duration of the disease ($p: 0.237$).

The thickness of the choroid, peripapillary retina nerve fiber layer (RNFL) and macula in patients with inflammatory bowel disease (IBD), healthy individuals of study participants are shown in table 2, 3, and 4 respectively.

All of the choroidal thickness measurements were not found to significantly differ between patients with CD, UC and control subjects ($p > 0.05$). Similarly, there was

Table 1: Demographic characteristics of the groups

Demographics	Crohn's disease (n:26)	Ulserative colits (n:31)	Control (n:29)	p-value
Age (year)	44.2 ± 12.30	44.45 ± 11.35	42.06 ± 12.88	0.696*
Male:female ratio	16:10	22:9	13:16	0.115 [^]
Duration of disease (years)	4.50 ± 2.25	5.35 ± 3.01	N/A	0.237 ⁺

*: One-way ANOVA test results, [^]: Chi-Square test results, ⁺: Independent sample t-test results, BCVA: Best-corrected visual acuity

Table 2: Results and comparison of choroidal thickness in different regions

Choroid	Crohn's disease (n:26)	Ulserative colits (n:31)	Control (n:29)	p values*
Nasal1000	284.63±78.52	293.19±79.97	287.76±76.77	0.93
Nasal2000	243.36±67.47	237.19±65.07	235.84±60.10	0.92
Fovea	316.42±77.45	316.73±79.78	327.00±90.09	0.88
Temporal1000	281.63±81.54	292.76±83.02	300.72±82.23	0.74
Temporal2000	275.15±82.32	280.57±69.33	281.00±75.73	0.96

*: One-way ANOVA test results

Table 3: Results and comparison of retina nerve fiber layer thickness in different regions

RNFL	Crohn's disease (n:26)	Ulserative colits (n:31)	Control (n:29)	p values*
Global	97.25±9.34	100.61±8.31	98.60±11.62	0.50
Superior	119.00±16.26	122.57±11.27	120.62±17.12	0.72
Temporal	69.00±9.72	72.00±10.24	73.48± 17.06	0.51
Inferior	127.55±16.39	131.73±14.08	126.48±19.53	0.50
Nasal	74.95±12.38	75.30±12.58	75.16± 14.74	0.99

*: One-way ANOVA test results. RNFL: retina nerve fiber layer thickness.

Table 4: Results and comparison of macular thickness in different regions

MT	Crohn's disease (n:26)	Ulserative colits (n:31)	Control (n:29)	p values*
Central	220.20±20.06	217.03±15.74	221.68±19.08	0.65
Nasal 1	341.40±13.06	344.69±19.37	336.44±14.85	0.19
Nasal 2	313.30±12.85	314.46±15.11	310.56±17.63	0.65
Inferior 1	341.35±12.01	343.03±16.68	335.88±15.42	0.22
Inferior 2	289.70±12.29	288.11±9.17	288.68±13.57	0.90
Temporal 1	330.80±10.90	330.84±15.63	326.28±15.10	0.44
Temporal 2	285.40±9.92	283.80±10.43	286.28±13.27	0.73
Superior 1	344.90±10.09	343.76±17.79	338.64±15.25	0.32
Superior 2	298.95±12.54	297.92±13.52	297.04±15.64	0.90

*: One-way ANOVA test results. MT: macular thickness.

no significant difference detected in the thickness of the superior, inferior, temporal, and nasal quadrant RNFL between the IBD and control subjects ($p>0.05$). The evaluations in all of the macular thickness show no significant difference between the IBD and control subjects ($p>0.05$)

DISCUSSION

In our study, we hypothesized that chronic inflammation seen in patients with IBD can affect choroidal, retinal or peripapillary retina nerve fiber layer thickness. To the best of our knowledge, this is the first study to use OCT to

examine RNFL, macula, choroid thickness of the eye in IBH patients.

The overall incidence of posterior segment manifestations is low, at less than 1% in patients with IBD, but the serious visual loss can result from the vitreous inflammation and retinal ischemia associated with retinal vasculitis.¹¹ Such occlusive arterial pathology may also manifest itself as a branch retinal artery occlusion. Central and branch retinal vein occlusions, cystoid macular edema, multifocal central serous retinopathy, serous retinal detachments, choroidal folds, and macular hemorrhages have all been reported in patients with IBD.¹¹

Katsanos et al. performed a review of orbital and optic nerve involvement in IBD.¹² It was found that optic nerve impairment can occur as a result of damage of the optic nerve tissue per se, as a result of inflammation and/or ischemia, due to intracranial hypertension, and secondary to anti-TNF agents.

Neuro-ophthalmic complications, optic neuritis is the most common type of optic neuropathy encountered in IBD and optic disc edema has been reported as occurring in 4% of patients with ocular complications of IBD.¹ Retrobulbar neuritis, papillitis, and neuroretinitis have all been described in IBD and may be associated with iritis, vitreous inflammation, retinal vasculitis, and choroiditis.¹

Shulman et al. investigated peripapillary and macula thickness in cases with acute anterior uveitis (ankylosing spondylitis, idiopathic uveitis, reactive arthritis, and CD) and reported that the thickness of the peripapillary RNFL was greater than that of healthy individuals.¹³ Unlikely, our study found that RNFL thickness was similar in IBD and control subjects. This may be due to the absence of active or previous history of uveitis in patients in this study.

The choroidal layer is the most vascularized layer in the eye, so it can play a role in many ophthalmologic diseases. OCT applications (EDI-OCT) allowing cross-sectional imaging of the choroid, and several studies have demonstrated that choroidal thickness changes in ocular diseases such as age-related macular degeneration, high myopia, chorioretinal atrophies, Vogt-Koyanagi-Harada disease, Behçet's disease, sarcoidosis uveitis, and polypoidal choroidal vasculopathy.¹⁴ Kola et al. reported increased choroidal thickness in patients with ankylosing spondylitis compared to healthy controls.¹⁰ The authors proposed that chronic systemic inflammation may play an important role in the thickening of the choroid layer in patients with ankylosing spondylitis.¹⁰ However, found no significant correlation between the choroidal thickness and systemic inflammatory markers.¹⁰ Onal et al. demonstrated that choroidal thickness was similar between patients with

IBD and healthy control subjects.¹⁵ Similarly, according to our results, there was no statistically significant difference with respect to choroidal when compared to healthy subjects.

Akay et al in inflammatory bowel patients and Yuvacı et al in patients, did not detect any difference in central macular thickness compared to healthy volunteers.^{16,17} Similarly, according to our results, there was no statistically significant difference in macular thickness when compared to healthy subjects. Besides the central region, our study showed that no difference in whole macular rings regions.

This study had some limitations. The outcomes of the present study cannot be generalized because of the small sample size. If the study was performed in patients in attack period-duration it was possible to obtain more significantly different measurements. This was not a long-standing study, so the progress of disease and changes in the parameters are unknown. Despite these limitations, this study is important because there are no published data investigating the effects of chronic inflammation in IBD patients using RNFL, CT, and macula parameters together.

In conclusion, inflammatory bowel diseases such as Crohn's disease and ulcerative colitis have no change in the choroid, RNFL, and macular thickness. Further, prospective and larger studies are needed.

Declaration of Interest

The authors notice that no conflict of interest for this article. All authors are responsible for the content and writing of this manuscript.

Disclosure Statement

The authors certify that they have no affiliations or in any organization with any financial interest or non-financial interest in the subject matter or materials discussed in this manuscript.

Financial Support or Funding

There is no funding or financial support for this research.

REFERENCES

1. Knox DL, Schachat AP, Mustonen E. Primary, Secondary and Coincidental Ocular Complications of Crohn's Disease. *Ophthalmology*. 1984;91:163-73.
2. Zhang YZ, Li YY. Inflammatory bowel disease: Pathogenesis. *World J Gastroenterol*. 2014;20:91-9.
3. Souza MHL, Troncon LE de A, Rodrigues CM, et al. Evolução da ocorrência (1980-1999) da doença de Crohn e da retocolite ulcerativa idiopática e análise das suas características clínicas em um hospital universitário do sudeste do Brasil. *Arq Gastroenterol*. 2002;39:98-105.

4. Felekis T, Katsanos K, Kitsanou M, et al. Spectrum and frequency of ophthalmologic manifestations in patients with inflammatory bowel disease: A prospective single-center study. *Inflamm Bowel Dis*. 2009;15:29-34.
5. Thomas AS, Lin P. Ocular manifestations of inflammatory bowel disease. Vol. 27, *Current Opinion in Ophthalmology*. 2016. 552-60.
6. Czompa L, Barta Z, Ziad H, et al. Corneal Manifestations of Inflammatory Bowel Disease. *Semin Ophthalmol*. 2019;34:543-50.
7. Fine S, Nee J, Thakuria P, et al. Ocular, Auricular, and Oral Manifestations of Inflammatory Bowel Disease. Vol. 62, *Digestive Diseases and Sciences*. 2017. 3269-79.
8. Hassenstein A, Meyer CH. Clinical use and research applications of Heidelberg retinal angiography and spectral-domain optical coherence tomography - A review. Vol. 37, *Clinical and Experimental Ophthalmology*. 2009. p. 130-43.
9. Güngör SG, Akkoyun I, Reyhan NH, et al. Choroidal thickness in ocular sarcoidosis during quiescent phase using enhanced depth imaging optical coherence tomography. *Ocul Immunol Inflamm*. 2014;22:287-93.
10. Kola M, Kalkisim A, Karkucak M, et al. Evaluation of choroidal thickness in ankylosing spondylitis using optical coherence tomography. *Ocul Immunol Inflamm*. 2014;22:434-8.
11. Ernst BB, Lowder CY, Meisler DM, et al. Posterior Segment Manifestations of inflammatory Bowel Disease. *Ophthalmology*. 1991;98:1272-80.
12. Katsanos A, Asproudis I, Katsanos KH, et al. Orbital and optic nerve complications of inflammatory bowel disease. Vol. 7, *Journal of Crohn's and Colitis*. 2013. 683-93.
13. Shulman S, Goldenberg D, Habet-Wilner Z, et al. Optical coherence tomography characteristics of eyes with acute anterior uveitis. Vol. 14, *Israel Medical Association Journal*. 2012. 543-6.
14. Adhi M, Lau M, Liang MC, et al. Analysis of the thickness and vascular layers of the choroid in eyes with geographic atrophy using spectral-domain optical coherence tomography. Vol. 34, *Retina*. 2014. 306-12.
15. Onal IK, Yuksel E, Bayrakceken K, et al. Measurement and clinical implications of choroidal thickness in patients with inflammatory bowel disease. *Arq Bras Oftalmol*. 2015;78:278-82.
16. Akay F, Genc H, Kumbul YÇ. Effect of The Inflammatory Bowel Diseases on Choroidal and Macular Thickness. *SDÜ Tıp Fakültesi Derg* [Internet]. 2018 Sep 1; Available from: <http://dergipark.gov.tr/doi/10.17343/sdutfd.434235>
17. Yuvacı İ, Atum M, Pangal E, et al. The Investigation of the Relationship Between Retinal and Choroidal Thickness By Sedimentation Rate for Patients with Ankylosing Spondylitis. *Sak Med J* [Internet]. 2018 Dec 31;8:775-81.